DOI: https://doi.org/10.66984/jsmdc.v12.i01.cr.01.

Case Report

Co-Occurrence of Synovial Chondromatosis and Distal Humeral Osteochondroma of the Elbow in a Young Athlete: A Case Report

Farooq Azam Khan

ABSTRACT

Synovial chondromatosis and osteochondroma rarely present concurrently in the elbow. We report a 19-year-old male football goalkeeper with an 8 month history of progressive right elbow pain and restricted range of motion (flexion 90°, extension 30°) likely related to repetitive microtrauma. Imaging revealed multiple intraarticular small, loose bodies; known as rice bodies consistent with synovial chondromatosis and a distal humeral osteochondroma measuring >2.5 cm. In the first stage, arthroscopic synovectomy with excision of rice bodies was performed, while the osteochondroma was left for a planned second stage open resection. This case highlights the importance of staged surgical management and rehabilitation in restoring function in a young patient with concurrent benign elbow pathologies.

Keywords: *Synovial chondromatosis. Osteochondroma. Arthroscopy. Synovectomy.*

INTRODUCTION

Primary synovial chondromatosis is a rare metaplastic disorder with an estimated incidence of approximately 1 per 100,000 individuals, and the elbow is an uncommon site of involvement.[1] Osteochondroma is the most common benign bone tumor, representing approximately 30% of all benign bone tumors; however, its occurrence in an intraarticular location of the distal humerus is exceedingly rare.[2] The simultaneous occurrence of these two distinct entities is exceptionally uncommon, with only a few isolated cases reported in the literature.[3] Recurrent microtrauma has been suggested as a potential mechanism contributing to the pathogenesis and occurrence of secondary synovial chondromatosis.[4] This report illustrates the diagnostic evaluation, staged surgical treatment, and early post-operative rehabilitation of a goalkeeper suffering from both conditions.

CASE REPORT

A 19-year-old male football goalkeeper presented with an eight months history of insidious-onset pain that was gradually worsening. He also reported a progressive restriction of movement in his dominant right elbow. He ascribed his symptoms to recurrent activities while training as a goalkeeper. There was no history of any comorbid condition. A painful arc of motion with a mechanical block to elbow movement, limited flexion to 90°, and a 30° extension deficit were identified on clinical examination. Routine laboratory investigations showed no abnormalities. Plain radiographs (Figure 1), magnetic resonance imaging (MRI) (Figure 2a), and computed tomography (CT) (Figures 2b and 2c) revealed an osteochondroma exceeding 2.5 cm in size arising from the anterior and distal sides of the humerus, in addition to multiple loose intraarticular (rice) bodies, establishing the co-occurrence of synovial chondromatosis.[5]

A staged approach was undertaken for the management. The initial procedure was arthroscopic synovectomy with removal of rice bodies, followed by an open excision of osteochondroma during a subsequent surgery. The purpose of this approach was to relieve pain, restore elbow mobility, and facilitate the patient to resume sporting activities.

The procedure was performed under general anesthesia using strict aseptic measures. Standard anteromedial, anterolateral, and posterior arthroscopic portals were created to access the elbow joint after placing the patient in the lateral decubitus position. Multiple intra-articular cartilaginous rice bodies were identified on diagnostic arthroscopy (Figure 3a), followed by an extensive synovectomy with removal of all accessible rice bodies (Figure 3b).[6] Arthroscopic excision was not suitable for osteochondroma owing to the size, location, and proximity to critical neurovascular structures. The lesion was left in place for a planned second-stage open excision.[7]

The diagnosis of synovial chondromatosis was confirmed on histopathological examination. The focus of immediate postoperative rehabilitation was edema control and introduction of gentle assisted exercises while avoiding aggressive stretching. The rehabilitation process gradually progressed to

Sharif Medical & Dental College, Sharif Medical City. Sharif Medical City Road, Off Raiwind Road, Jati Umra, Lahore 54000, Pakistan.

Correspondence: Dr. Farooq Azam Khan
Head & Professor Department of Orthopedics
Sharif Medical & Dental College, Lahore
E-mail: farooq.azam@sharifmedicalcity.org

Received: May 3, 2026; Accepted: May 24, 2026

functional range of motion exercises from the second postoperative week onward.

A planned second stage open excision via anteromedial and posterolateral approaches was carried out 8 weeks after the initial procedure. Following completion of both surgical stages, the patient achieved normal elbow motion, pain relief, and return to competitive sporting activity.

DISCUSSION

The elbow's constrained anatomy makes it particularly susceptible to mechanical impingement by space occupying lesions. Synovial chondromatosis typically presents with pain, swelling, mechanical locking, and restricted motion, whereas osteochondroma commonly presents as a painless bony prominence and is rarely encountered in an intraarticular location around the elbow.[1,2] The simultaneous occurrence of the two pathologies is exceptionally uncommon, making diagnosis and management challenging.[2,3] In athletes subjected to repetitive valgus and axial loading, microtrauma has been hypothesized to induce synovial metaplasia.[4]

In the present case, the coexistence of numerous intraarticular rice bodies with a large distal humeral osteochondroma resulted in significant functional limitation and a mechanical block to elbow motion. Some reports have described delayed diagnosis because symptoms are often attributed to sports related overuse injuries or repetitive microtrauma.[4]

Figure 1: Anteroposterior and Lateral Radiographs of the Right Elbow showing a Radiopaque Mass Arising from the Anterior Distal Humerus, Consistent with Osteochondroma

Figure 2a: Sagittal T2-Weighted MRI Demonstrating Multiple Intraarticular Rice Bodies and an Anterior Distal Humeral

Figure 2b: Sagittal CT Image Demonstrating Multiple Intraarticular Rice Bodies within the Anterior Compartment of the

Figure 2c: (c) Axial CT Image Demonstrating the Distal Humeral Osteochondroma and Associated Intraarticular Rice Bodies Elbow

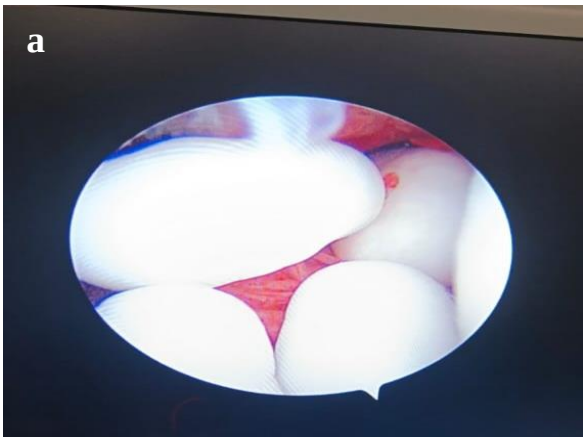

Figure 3a: Arthroscopic View of the Elbow Joint showing Rice Bodies

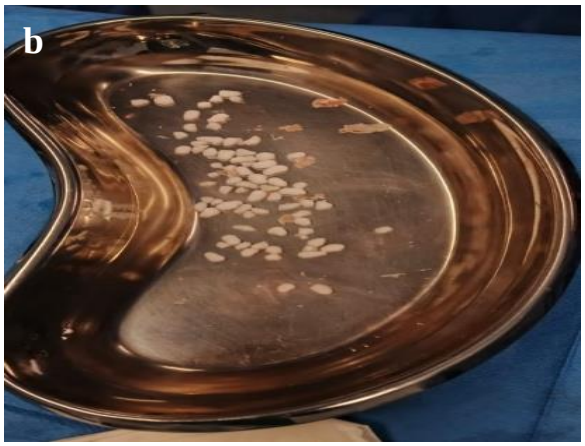

Figure 3b: Rice Bodies Removed from the Elbow Joint

Arthroscopic synovectomy with removal of rice bodies is considered the standard treatment for synovial chondromatosis because it provides superior visualization, lower morbidity, and faster rehabilitation.[1,6] A study described the arthroscopic management of elbow synovial chondromatosis and highlighted the advantages of arthroscopy, including shorter rehabilitation and improved patient satisfaction. However, long term surveillance is necessary, as recurrence of synovial chondromatosis has been reported in a small proportion of patients.[6]

Management of osteochondromas around the elbow depends on lesion size, location, symptoms, and proximity to neurovascular structures. Larger osteochondromas are associated with an increased risk of incomplete excision and iatrogenic neurovascular injury, whereas arthroscopic excision is generally reserved for carefully selected cases.[7] A study published in 2024 reported successful surgical treatment of intraarticular elbow osteochondroma with favourable functional outcomes, supporting the role of complete lesion excision in symptomatic patients.[8] The confined anatomy of the elbow must be considered during surgical planning to balance complete tumor excision with preservation of surrounding neurovascular structures.[7]

Arthroscopic soft tissue removal followed by planned open osteochondroma excision was adapted, as arthroscopic management may not be optimal for all intraarticular osteochondromas, particularly when lesion characteristics raise concerns regarding complete and safe resection.[9]

CONCLUSION

The co-occurrence of synovial chondromatosis and distal humeral osteochondroma of the elbow is very rare and may present with significant pain, mechanical blockage, and limited motion in young athletes. Accurate radiological evaluation is necessary for diagnosis and treatment planning. In this case, arthroscopic synovectomy with removal of rice bodies provided effective initial management, while staged open excision of the osteochondroma was planned to ensure safe and complete resection. This case illustrates the importance of individualized surgical planning and rehabilitation in achieving optimal functional recovery and resume to sporting activity.

REFERENCES

1. Deng X, Liu S, Liu H. Synovial chondromatosis: novel advances in understanding the pathogenesis and in diagnostic strategies (review). Mol Med Rep. 2026; 33(1):33. doi:10.3892/mmr.2025.13743.

2. Alabdullrahman LW, Mabrouk A, Byerly DW. Osteochondroma. In: StatPearls [Internet]. Treasure Island (FL): StatPearls Publishing; 2026. Available from: https://www.ncbi.nlm.nih.gov/books/NBK544296.

3. Shin SE, Nam JW. Concurrent osteochondroma and synovial chondromatosis of the temporomandibular joint inducing unnoticed occlusal changes: a rare case report. Kor J Oral Maxillofac Pathol. 2024; 48(6):99-103. doi:10.17779/KAOMP.2024.48.6.003.

4. Mangual D, Olivella G, Ramirez N, Astacio E, Bibiloni J, Foy-Parrilla C. Post-traumatic tenosynovial chondromatosis following a triquetrum fracture: a case report. Oxf Med Case Reports. 2021; 2021(4):omab007. doi:10.1093/omcr/omab007.

5. Wang L, Jin Y, Huang H, Yang Z, Ding F, Xu X, et al. Rice body synovitis in pediatrics: three different case reports. Front Pediatr. 2024; 12:1391229. doi:10.3389/fped. 2024.1391229.

6. Chan SK, Lui TH. Arthroscopic management of synovial osteochondromatosis of the elbow. Arthroscopy Techniques. 2021;10(4):e1103-8. doi: 10.1016/j.eats.2020. 12.009.

7. Nouri A, Lari A, Almuhaisen N, Eldesouky I, Shaker H, Ali R, et al. An extra-osseous intraarticular osteochondroma of the elbow. JSES Int. 2022; 7(1):167-70. doi:10.1016/j.jseint.2022.08.018.

8. Almoftery I, Hassan A, Alshumrani Y, Alqahtani AMA. Intraarticular osteochondroma in the elbow: diagnosis and surgical treatment in an 8-year-old boy. Am J Case Rep. 2024; 25:e943927. doi:10.12659/AJCR.943927.

9. Reikersdorfer KN, Wright C, Puzzitiello RN, Zotter SF, Paschos NK. Arthroscopic excision of the intraarticular osteochondroma: a technical note. Arthrosc Tech. 2024; 14(5):103337. doi:10.1016/j.eats.2024.103337.

How to cite: *Khan FA. Co-occurrence of synovial chondromatosis and distal humeral osteochondroma of the elbow in a young athlete: a case report. JSMDC. 2026; 12(01):65-68. doi:https://doi.org/10.66984/jsmdc.v12.i01.cr.01.*