

# Morphometric Analysis of the Infraorbital Foramen in Dry Human Adult Skulls in a Local Population

Nadia Ahmad, Ammara Ghafoor, Mamoona Shoukat, Nausheen Raza, Fariha Ahmad

## ABSTRACT

**Objective:** To evaluate morphometric parameters and precise anatomical position of infraorbital foramina in reference to its surrounding important anatomical landmarks in adult human skulls.

**Methodology:** A cross-sectional study was done on sixty adult dry skulls of unknown age and sex collected from the Anatomy Department of Sharif Medical and Dental College, Lahore. The skulls were assessed to determine the shape, vertical, and transverse diameter of infraorbital foramina, the distances between infraorbital foramina and the infraorbital margins, nasion, anterior nasal spine, and superior orbital foramen with the help of vernier calipers. Data was analyzed using Statistical Package for the Social Sciences (SPSS) version 26.

**Results:** The mean vertical diameter of the infraorbital foramen (IOF) was  $4.14 \pm 0.83$  mm, the mean horizontal diameter of IOF was  $4.88 \pm 1.11$  mm, the mean distance of IOF from the infraorbital margin (IOM) was  $6.32 \pm 1.29$  mm, from nasion was  $44.61 \pm 2.84$  mm, from supraorbital foramen was  $41.98 \pm 2.78$  mm, and from the anterior nasal spine was  $34.14 \pm 3.6$  mm. One-way ANOVA showed a statistically significant difference ( $p$ -value=0.001) in the mean vertical diameter of the IOF on the right and left sides of the skull. The shape of IOF was predominantly oval.

**Conclusion:** The mean vertical diameter of IOF on the left side was higher as compared to the right side of the skulls and the difference was statistically significant. The predominant shape of IOF was oval. The knowledge of the diameters and distance of IOF from various landmarks on the skull can aid the surgeons in careful preoperative assessment of patients who are candidates for maxillofacial surgeries and regional block anesthesia.

**Keywords:** Human skull. Infraorbital foramen. Infraorbital nerve.

## INTRODUCTION

The infraorbital foramen is a small, rounded opening located on the upper portion of the maxilla near the infraorbital margin. It is the anterior continuation of the infraorbital groove through which the infraorbital nerve, infraorbital vein, and artery pass.<sup>1</sup> The nerve and vessels course through the floor of the orbit and supply upper teeth and maxillary sinuses through its smaller branches, posterior superior alveolar nerve, and anterior superior alveolar nerve.<sup>2</sup> It may vary in shape and size and is a very important reference point in various anesthetic and surgical procedures including oral and maxillofacial surgeries. The knowledge of its positional variations may help to decrease the risk in various orbital surgeries. For example, in paranasal and facial surgeries, an infraorbital nerve block is given in trigeminal neuralgia (an unexplained peripheral nerve pain). A neurectomy is done on the infraorbital nerve through the infraorbital foramen approach.<sup>3</sup> Infraorbital plexuses are present near infraorbital foramina and are more prone to injury in orbital surgeries. So, the infraorbital foramen is an important landmark to avoid damage to important

nerve plexuses during orbital surgeries. The infraorbital foramen forms a communication between the cranial cavity and orbit, nose, and paranasal sinuses.<sup>4</sup> Sometimes an accessory foramen is seen in the area around the normal infraorbital foramina which is connected to the infraorbital canal and transmits various smaller branches of internal nasal, external nasal, inferior palpebral, and superior labial nerves to supply the surface of the face. An accessory infraorbital foramen could be a cause of many complications in certain surgeries for example in Le fort osteotomy because it causes disturbances in the neurosensory supply of infraorbital nerve as few branches pass through this accessory foramen.<sup>5</sup> A study revealed an accessory infraorbital foramen to be present in 2.2% of males and 4.8% of females of the English population.<sup>6</sup> The relation of the morphology of infraorbital foramina in parallel to accessory infraorbital foramina is important for the surgeon to proceed with the surgery.<sup>7</sup> So, the morphometric analysis of IOF provides important information to avoid traumatic surgeries that may lead to paresthesia or hypoesthesia of the face by iatrogenic injury to the infraorbital nerve and vessels. Hence, the present study was conducted to evaluate morphometric parameters and precise anatomical position of infraorbital foramina in reference to anatomical landmarks in the adult human skulls among the local population of Pakistan.

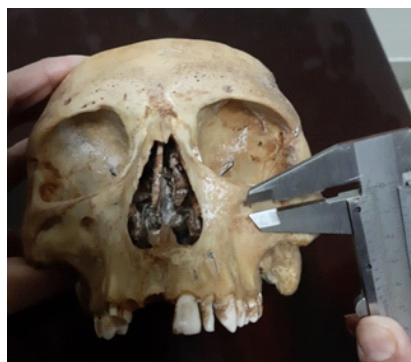## METHODOLOGY

This cross-sectional study was conducted on 60 adult

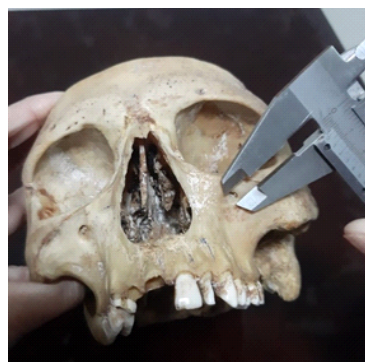Sharif Medical & Dental College, Sharif Medical City,  
Sharif Medical City Road, Off Raiwind Road, Jati Umra,  
Lahore 54000, Pakistan.

Correspondence: Dr. Nadia Ahmad  
Associate Professor Department of Anatomy  
Sharif Medical & Dental College, Lahore  
E-mail: diaejaz\_74@hotmail.com

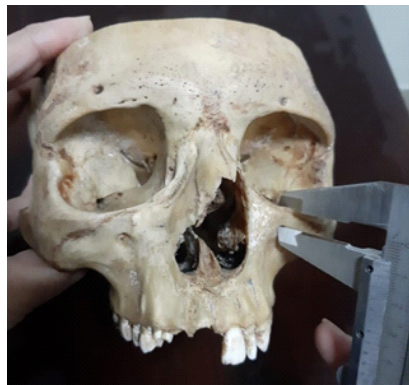Received: November 10, 2022; Accepted: November 29, 2022



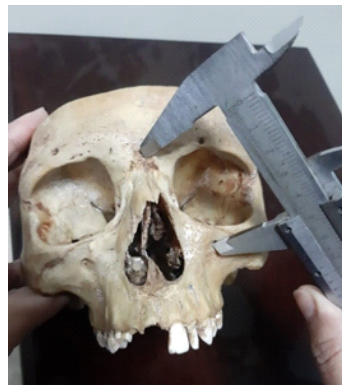a. Vertical Diameter of IOF



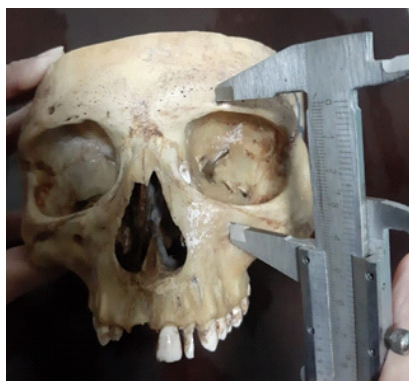b. Horizontal Diameter of IOF



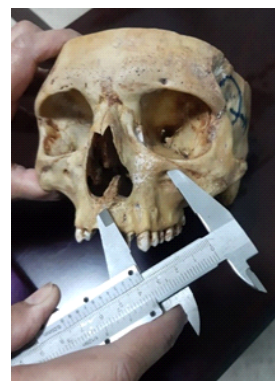c. Distance between Infraorbital Foramen and Infraorbital Margin



d. Distance between Infraorbital Foramen and Nasion

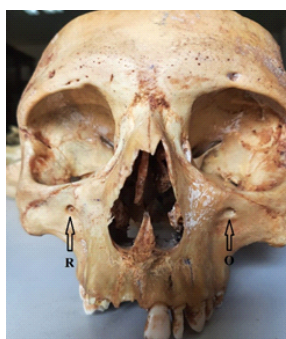

e. Distance between Infraorbital Foramen and Supraorbital Foramen



f. Distance between Infraorbital Foramen and Anterior Nasal Spine

**Figure 1: Morphometric Measurements of Infraorbital Foramen (a-f)**



**Figure 2: Shape of Infraorbital Foramen [Round (R), Oval (O)]**

dry skulls collected from the Department of Anatomy, Sharif Medical & Dental College, Lahore after approval from the ethical committee of the institute. The skulls of unknown gender and age with no visible gross deformity or pathology were included while the skulls with alveolar bone resorption or damaged orbital and nasal regions were excluded from the study. The right and left sides of the adult skulls were divided into two groups. The maximum diameter (vertical and horizontal) of the IOF, the distances between the IOF and the infraorbital margin, anterior nasal spine (ANS), nasion (Na), and supraorbital foramina (SOF) of both groups (right and left) were measured by using a vernier caliper (Figure 1). The shape of the infraorbital foramen was also noted (Figure 2). To minimize the observer's error, all measurements were recorded by two investigators and the mean was taken for final analysis.<sup>8</sup>

### STATISTICAL ANALYSIS

Data analysis was done using Statistical Package for the Social Sciences (SPSS) version 26. Mean and standard deviation was calculated for quantitative parameters.

One-way ANOVA was applied for quantitative parameters and a p-value  $\leq 0.05$  was considered statistically significant.

### RESULTS

The minimum, maximum, mean vertical & horizontal diameters of IOF, and the distance of IOF from the infraorbital margin, nasion, supraorbital foramen, and anterior nasal spine on the right side, left side, and both sides together (total) in millimeters is shown in Table 1. On analyzing with ANOVA, a statistically significant difference (p-value=0.001) was observed in the mean vertical diameter of the IOF between the right and left sides. However, no other statistically significant difference was observed in the rest of the parameters (Table 1). The shape of infraorbital foramen was recorded as round and oval with a predominantly oval shape (69%). On the right side 62 % whereas, 72% on the left side had an oval shape (Table 2).

The means of various parameters of IOF on the right and left sides of the skull are displayed in the bar chart in Figure 3.

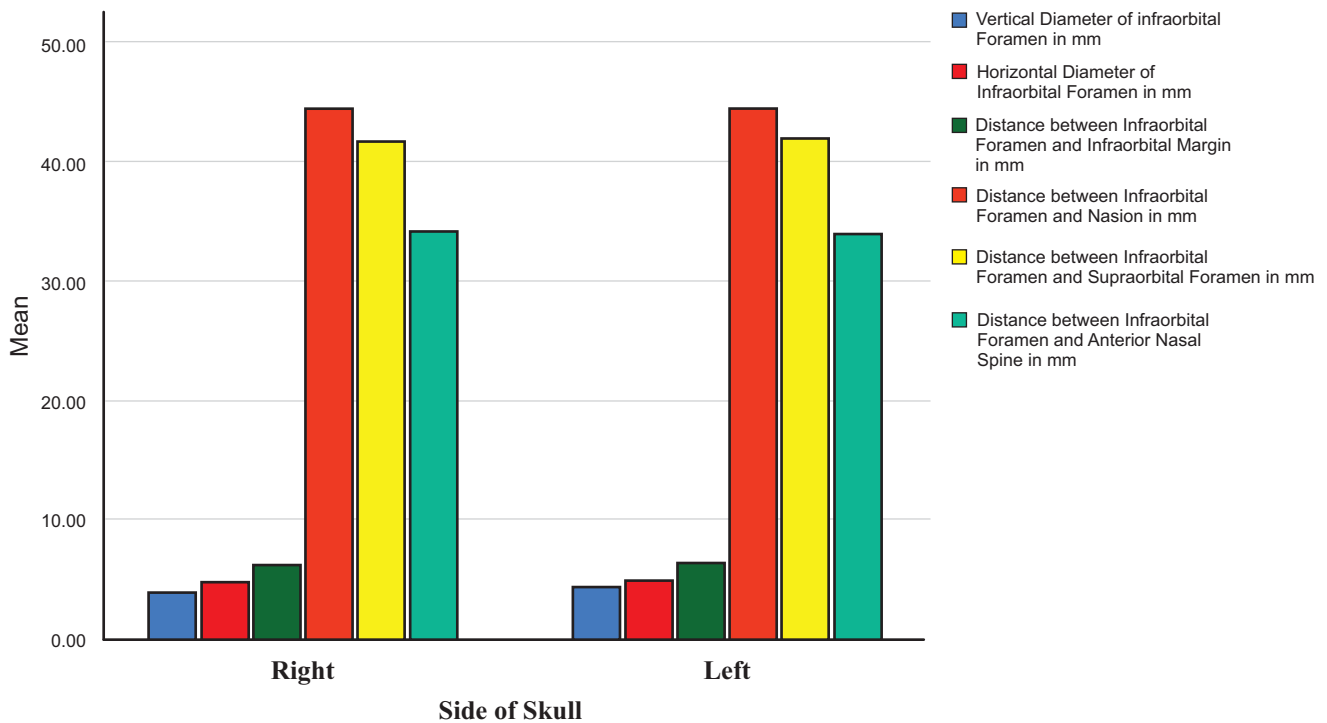
**Table 1: Morphometric Measurements on Right, Left, and Total IOF**

Sr. No.	Parameters	Side of Skull	Total No.	Minimum (mm)	Maximum (mm)	Mean±SD (mm)	p-value
1	Vertical Diameter of Infraorbital Foramen	Right	60	2.6	5.2	3.9±0.66	0.001*
		Left	60	3.1	7.2	4.38±0.91	
		Total	120	2.6	7.2	4.14±0.83	
2	Horizontal Diameter of Infraorbital Foramen	Right	60	2.4	7.6	4.81±1.18	0.485
		Left	60	2.7	8.2	4.95±1.03	
		Total	120	2.4	8.2	4.88±1.11	
3	Distance between Infraorbital Foramen and Infraorbital Margin	Right	60	4	9.8	6.32±1.32	0.978
		Left	60	4	10.3	6.32±1.28	
		Total	120	4	10.3	6.32±1.29	
4	Distance between Infraorbital Foramen and Nasion	Right	60	38.9	52	44.65±2.94	0.868
		Left	60	38.1	53	44.56±2.76	
		Total	120	38.1	53	44.61±2.84	
5	Distance between Infraorbital Foramen and Supraorbital Foramen	Right	60	37	47.4	41.82±2.46	0.515
		Left	60	35	49.6	42.15±3.07	
		Total	120	35	49.6	41.98±2.78	
6	Distance between Infraorbital Foramen and Anterior Nasal Spine	Right	60	27	49.2	34.28±4.28	0.676
		Left	60	28.9	45.1	34.01±2.81	
		Total	120	27	49.2	34.14±3.6	

\*Significant p-value  $\leq 0.05$

**Table 2: Comparison of Shape of Infraorbital Foramen among Study Groups**

Shape	Round	Oval	Total
Right	23(38%)	37(62%)	60
Left	17(28%)	43(72%)	60
Total	33%	67%	100%



**Figure 3: Mean of Morphometric Parameters of Right and Left Infraorbital Foramen**

**DISCUSSION**

Infraorbital foramen is an important landmark for various surgeries including maxillofacial surgeries. Any damage to the neurovasculature during infraorbital nerve block might cause numbness of the area (lower eyelid, lateral wall of the nose and upper lip) supplied by the nerve.<sup>2</sup> So identification of the precise position of IOF is helpful in various diagnoses and clinical procedures like management of pain in trigeminal neuralgias and various aesthetic procedures.<sup>9</sup>

The current study showed the presence of bilateral infraorbital foramina in all sixty skulls which corresponds with the study conducted on 52 dry human skulls in the department of Anatomy, Coimbatore Medical College, India. The study revealed that the infraorbital foramen was single in 50 skulls on both sides.<sup>10</sup> The shape of an infraorbital foramen in the current study was found to be predominantly oval (67%). Our study was in accordance with the results of another study done by Nanayakkara et al. They found the oval shape in 38.6% on the right side and 36.3% on the left side.<sup>2</sup> Furthermore, no accessory foramina were observed in any skull which is not in line with the observation of a similar study where 18.2% accessory foramina were observed.<sup>11</sup> An Indian study also showed that the accessory foramina were present in 2 out of 52 skulls, one skull had unilateral accessory foramen while the other skull had bilateral accessory foramina. This contradicts the present study findings.<sup>10</sup> This study also showed a significant difference in the

vertical diameter of the right and left infraorbital foramen. The vertical diameter of the left IOF ( $4.38 \pm 0.91$  mm) was higher than the right IOF ( $3.9 \pm 0.66$  mm). Similar results were reported in another study by Tewari et al.<sup>12</sup> Another study by Veeramuthu et al., on 105 adult dry skulls found the mean values of vertical diameters of IOF as  $3.88 \pm 1.17$  mm on the right side and  $3.68 \pm 0.89$  mm on the left side.<sup>13</sup> The slight difference in vertical diameters of these studies might be due to the different populations under study.

In the present study vertical diameter of IOF showed a significant difference between the right and left side ( $p=0.001$ ) which is contrary to the previous study where non-significant results were observed.<sup>4</sup> This might be due to the different populations under study. While the distances between IOF and supraorbital foramina, anterior nasal spine, nasion, and superior orbital margin showed non-significant results that are in accordance with another study.<sup>4</sup> In the current study the transverse diameter of IOF was statistically non-significant which is contradictory to the previous research where significant results were observed.<sup>14</sup> This might be due to racial differences, larger sample size, and use of 3-D cone beam computed tomography. In our study, the mean distance between the IOF and IOM was found to be  $6.32 \pm 1.29$  mm which is parallel with a study done earlier where the same was  $6.6 \pm 1.65$  mm.<sup>15</sup> In another study by Karpagam et al., the mean distance between the IOF and IOM was found to be  $3.69 \pm 1.01$  mm which is in contrast to our study.<sup>16</sup>



## CONCLUSION

The mean vertical diameter of IOF on the left side was higher as compared to the right side of the skulls and the difference was statistically significant. The predominant shape of IOF was oval. The knowledge of the diameters and distance of IOF from various landmarks on the skull can aid the surgeons in careful preoperative assessment of patients who are candidates for maxillofacial surgeries and regional block anesthesia.

## LIMITATIONS & RECOMMENDATIONS

The study needs to be seen in the context of its limitations. Small sample size and data from a single-center remains the major limiting factor. However, similarities of the findings with international research suggest the generalizability of these results. The knowledge of the diameters and distances of IOF from various landmarks on the skull among the local population can aid the surgeons in careful preoperative assessment of patients presenting for maxillofacial surgeries and regional block anesthesia.

## REFERENCES

1. Saheb SH, Shruthi BN, Havaladar PP. A study on position of infraorbital foramen. *IJAR*. 2017; 5(3.2):4257-60. doi:10.16965/ijar.2017.300.
2. Nanayakkara D, Peiris R, Mannapperuma N, Vadysinghe A. Morphometric analysis of the infraorbital foramen: the clinical relevance. *Anat Res Int*. 2016; 2016:7917343. doi:10.1155/2016/7917343.
3. Ebogo M, Olive N, Jacques E, Gislaine F, Daramsis H, Karl K, et al. Anthropometric measurements of infraorbital foramen in a selected Senegalese population; surgical implications. *Advances in Oral and Maxillofacial Surgery*. 2021; 4:100140. Available from: <https://www.sciencedirect.com/science/article/pii/S2667147621001278>.
4. Polo CL, Abdelkarim AZ, von Arx T, Lozanoff S. The morphology of the infraorbital nerve and foramen in the presence of an accessory infraorbital foramen. *J Craniofac Surg*. 2019; 30(1):244-53. doi:10.1097/SCS.0000000000004889.
5. Celebi A, Gulsun B. Evaluation of accessory mental foramen and accessory infraorbital foramen with cone-beam computed tomography in Turkish population. *Aust Endod J*. 2022. doi:10.1111/aej.12693.
6. Iwanaga J, Kikuta S, Kusukawa J, Tomaszewski KA, Walocha JA, Tubbs RS. Anatomic study of accessory infraorbital nerves and foramina: application for a better understanding of complications of le fort fractures and osteotomy. *J Oral Maxillofac Surg*. 2020; 78(5):717-23. doi:10.1016/j.joms.2020.01.004.
7. Ali IK, Sansare K, Karjodkar FR, Salve P. Cone beam computed tomography assessment of accessory infraorbital foramen and determination of infraorbital foramen position. *J Craniofac Surg*. 2018; 29(2): e124-6. doi:10.1097/SCS.0000000000004120.
8. Sokhn S, Challita R, Challita A, Challita R. The infraorbital foramen in a sample of the lebanese population: a radiographic study. *Cureus*. 2019; 11(12):e6381. doi:10.7759/cureus.6381.
9. Thunyacharoen S, Singsuwan P, Mahakkanukrauh P. Morphometric studies of supraorbital foramen, infraorbital foramen and mental foramen in a Thai population related with nerve blocks. *Int J Morphol*. 2022; 40(1):181-7. doi:10.4067/S0717-95022022000100181.
10. Rajeswari K, Rohinidevi M, Vimala V, Megala D. Morphometric analysis of infraorbital foramen in Human dry skulls. *Int J Anat Res*. 2016; 4(3):2725-9. doi:10.16965/ijar.2016.317.
11. Shin KJ, Lee SH, Park MG, Shin HJ, Lee AG. Location of the accessory infraorbital foramen with reference to external landmarks and its clinical implications. *Sci Rep*. 2020; 10(1):8566. doi:10.1038/s41598-020-65330-4.
12. Tewari S, Gupta C, Palimar V, Kathur SG. Morphometric analysis of infraorbital foramen in South Indian dry skulls. *Bangladesh J Med Sci*. 2018; 17(4):562-6. doi:10.3329/bjms.v17i4.38316.
13. Veeramuthu M, Varman R, Shalini, Manoranjitham. Morphometric analysis of infraorbital foramen and incidence of accessory foramen and its clinical implications in dry adult human skull. *Int J Anat Res*. 2016; 4(4):2992-3000. doi:10.16965/ijar.2016.391.
14. Bahsi I, Orhan M, Kervancioğlu P, Yalcin ED. Morphometric evaluation and surgical implications of the infraorbital groove, canal and foramen on cone-beam computed tomography and a review of literature. *Folia Morphol (Warsz)*. 2019; 78(2):331-43. doi:10.5603/FM.a2018.0084.
15. Masabni O, Ahmad M. Infraorbital foramen and pterygopalatine fossa location in dry skulls: anatomical guidelines for local anesthesia. *Anat Res Int*. 2017; 2017:1403120. doi:10.1155/2017/1403120.
16. Karpagam GN, Thenmozhi MS. A study of morphometric analysis of infraorbital foramen in South Indian dry skulls. *J Pharm Sci & Res*. 2016; 8(11):1318-9. Available from: <https://www.proquest.com/openview/6170b5d8dbc47f67d6495768f87653f5/1?pq-origsite=gscholar&cbl=54977>.

