


ISSN 2411-5096

JSMDC

Journal of Sharif Medical & Dental College



01/ Vol.1
June
2015



EDITORIAL BOARD

Patron

Muhammad Adnan Khan

Editor

Salma Haq

Associate Editors

Nausheen Raza
Nasir Raza Awan
Ahsen Nazir Ahmed

Assistant Editors

Ayma Syed
Haroon Tayyab

Managing Editor

Muhammad Anwer Sulehri

Members National

Junaid Sarfraz Khan
Muhammad Tahir
Humayun Maqsood
A. Majeed Chaudhry
Rakhshanda Tayyab
A. S. Chughtai
Qasim Saeed
Zafar Ahmed
Tahir Shafi
Mahmood Ali Malik
Iffat Batool

Members International

Rizwan Hamid (UK)
Theodore Tyberg (USA)

Editorial Assistant

Akram Tahir

Bibliographer

Akhwand Abdul Majeed Jawad

Statistician

Syed Asad Abbas

JSMDC

Journal of Sharif Medical & Dental College

Volume 01

Number 01

June 2015

EDITORIAL

I

Stem Cell Therapeutics: A Vague Biomedical Discipline or the Potential Answer

1-3

Muhammad Adnan Khan

ORIGINAL ARTICLES

II

Effect of Internal Limiting Membrane Peeling on Functional and Structural Outcome of Pars Plana Vitrectomy for Rhegmatogenous Retinal Detachment

4-8

Haroon Tayyab, Sana Jahangir, Syed Hassan Bin Usman Shah Bukhari, Samina Jahangir and Akhwand Abdul Majeed Jawad

The Frequency of Carcinoma Breast in Female Patients who Present with Blood Stained Nipple Discharge

9-11

Sidra Dil Muhammad, Muhammad Saad Faisal, Faiza Siddique, Ahsen Nazir Ahmed, Hira Mirza and Sadia Javaid

Efficacy of Percutaneous Trigger Finger Release

12-17

Farooq Azam Khan, Waqas Ali and Syed Saqib Raza

Correlation of mAgNOR and pAgNOR with Grade of Invasive Ductal Carcinoma of Breast

18-21

Khalida Ahtesham, Rozina Jaffer, Ambereen Anwar Imran, Munazza Hasan Sarosh and Majid Salaria

Clinical Spectrum, Progress of Disease, Grades of Severity and Outcome of Children with Dengue Fever

22-26

Syed Qamar Zaman, Emran Roshan and Arshad Mahmood

Single Incision Laparoscopic Appendectomy (SILA) by Conventional Laparoscopic Instruments: An Initial Single Surgeon Experience of 30 Cases of Uncomplicated Acute Appendicitis at Sharif Medical City Hospital, Lahore

27-30

Muhammad Saad Faisal, Sidra Dil Muhammad, Ahsen Nazir Ahmed, Muhammad Adnan Khan, Zille Maryum and Kausar Abbas

Variations in Intraocular Pressure During Valsalva Manoeuvre

31-33

Sana Jahangir, Haroon Tayyab, Samina Jahangir, Akhwand Abdul Majeed Jawad and Muhammad Asif Bashir

Comparison of Conventional and Minimal Invasive Dynamic Hip Screw Technique

34-38

Waqas Ali, Farooq Azam Khan and Khalid Mehmood

The JSMDC is published
biannually by
Sharif Medical & Dental College
Lahore, Paksitan.

**Editorial Correspondence
should be addressed to**

Editor JSMDC
Sharif Medical & Dental College
Sharif Medical City Road,
Off Raiwind Road, Jati Umra,
Lahore 54000, Pakistan.

Tel
(+92-42) 111-123-786

Fax
(+92-42)37860122

E-mail
editor@jsmdc.pk

Website
www.jsmdc.pk

Published by
ALIGARH Publisher
Ghalib Market, Gulberg III,
Lahore 54660
Ph:042-35771801-8
Fax:042-35759101
www.aligarh.com.pk

Annual Subscription Fee:
Pakistan: Rs 1000/-
US \$: \$ 100/-
UK £: £ 75/-

CASE REPORTS

III

**Minimal Surgical Intervention in Infected Necrotizing Pancreatitis:
An Experience of Laparoscopic Pancreatic Necrosectomy
at Sharif Medical City Hospital, Lahore** 39-41
Ahsen Nazir Ahmed, Muhammad Saad Faisal and Muhammad Adnan Khan

**A Rare Case of Disseminated Synovial Chondromatosis of Knee Joint:
A Case Report** 42-43
Farooq Azam Khan, Abbas Khan Bajwa and Syed Saqib Raza

INSTRUCTIONS TO AUTHORS

IV

Stem Cell Therapeutics: A Vague Biomedical Discipline or the Potential Answer

Muhammad Adnan Khan

Stem cell biomedicine is a fast growing technology providing tools for modifying the course of many diseases that currently are considered untreatable with conventional therapy. Stem cells are defined as cells having the potential of prolonged renewal with ability to differentiate into at least one particular cell type.¹

Although the most important advances in stem cell research have happened in last one decade, the concept of stem cells first appeared in 1868 by Haeckels in his scientific writings where he introduced the concept of “stanzelle” — a line of uncommitted cells capable of producing different types of cells.²

One of earliest breakthroughs was the isolation of mouse embryo stem cells (mESCs) by Lewis Kleinsmith and Barry Pierce in 1964.³ Although they were successful in separating and culturing mESCs outside mouse uterus, they were not able to differentiate them into anything but epithelial cells. Later, it was Evans and Kaufmann who, through the introduction of leukemia inhibitory factor (LIF), were able to prevent the differentiation of mESCs into epithelial cells, thus allowing them to grow under feeder cell free conditions.^{4,5}

Evolution of focus from mESCs to human embryonic stem cells (hESCs) was a long and tedious process, mainly because of ethical issues concerned with human embryo experimentation. It was in 1998 that Thompson reported in Science about their breakthrough with hESCs. They reported 5 cases of inner cell mass (ICM) isolation at blastocyst stage from human embryos that showed similar immortality, major surface antigens and ability to produce teratomas in immune modulated rats.⁶ Further research in hESCs showed many unique characteristics of hESCs that were different from mESCs.

The potential of ESCs of being pluripotent makes them an excellent candidate for generation of different somatic cell lineages. This prospect is heralded by the fact that these cells carry a very high risk of immune

rejection. Employing ESCs in a host is synonymous to implanting organ from another host into human body. Therefore, the next avenue of research was to induce pluripotency in somatic cells. Yamanaka's group extended their research work to prove that adult dermal fibroblasts could be reprogrammed into pluripotent cells. These cells are called induced pluripotent stem cells (iPSCs).⁷ The development of iPSCs is one of the most notable developments in last one decade of stem cell research. These cells open the gateways to generation of disease specific cell lines that can alter the course of pathology. But this discovery has come with a price of its own. Few of the challenges with iPSCs are potential possibility of induced tumorigenesis in the target tissue and full representative nature of single iPSCs cell line, which means that all iPSCs are not carrying the same potential of pluripotency.⁸ These problems can potentially restrict the clinical and practical role of iPSCs and intense research is being done to come up with a plausible solution to these problems. Therefore there is long distance between the coherent integration of disease with iPSCs but iPSCs still offer a tracer to the molecular functions of various human diseases.⁹

Despite the huge potential of further research in iPSCs, the most prolific source currently available for stem cells are mesenchymal stem cells (MSCs). Bone marrow is a potential source for MSCs and it was first demonstrated by Friedenstein who isolated cells from bone marrow which were identical to fibroblast in their structural and functional properties.¹⁰ These cells were considered an essential part of bone marrow cell pool playing pivotal role in supporting and nurturing hematopoietic function of bone marrow. It was also identified that these cells are also pluripotent and multipotent and have the ability to differentiate into various cellular lineages like adipocytes and chondrocytes.¹¹ In the late 90s, other sources of MSCs were identified apart from bone marrow. This is the reason, these cells were never called bone marrow stem cells; but called MSCs. These alternative sources included umbilical cord blood, adipose tissue, amnion, placenta and even the deciduous teeth of young people.^{12,13} The ease of obtaining MSC and their superior immunologic plasticity over other stem cells have brought them much closer to commercial breakthrough and we may soon see their end user benefits

Sharif Medical & Dental College, Sharif Medical City,
Sharif Medical City Road, Off Raiwind Road, Jati Umra,
Lahore 54000, Pakistan.

Correspondence: Dr. Muhammad Adnan Khan
Chief Executive Sharif Medical City
Executive Director Sharif Medical Research Center
E-mail: adnankhan@sharifmedicalcity.org

Received: March 16, 2015; Accepted: May 16, 2015.

because of their multipotency and ready availability. One of the most exciting aspects of stem cells research is tissue engineering. A lot of research has been done about tissue engineering processes and some success has also been embraced. The concept behind tissue engineering is to create a complete 3-dimensional living and working organ from mesenchymal stem cells. Although it may seem outrageous at the moment because it is known that stem cells grow well only when they are nurtured in a 3 dimensional environment like in embryo; researchers have built artificial scaffolds onto which stem cells have been grown and converted into functional organs. One source of these scaffolds is from cadavers. The donor organ is decellularized by stripping all the cells containing immunologic antigens and leaving behind a framework of extracellular matrix. This nature's platform can be used as a scaffold for the stem cells to grow and form complex 3-dimensional organs. A lot of research has been done in the field of organ decellularization since 1960s but the most significant results came in 2008 from Spain when such a bioengineered trachea was transplanted in a human to replace a diseased trachea. The original trachea was obtained from a cadaver and was decellularized and transplanted in host subject.¹⁴ This surgery was a huge success and further extension of this research has been applied in paediatric population as well. Trachea proved to be a simpler organ to bioengineer but other organs like heart, lungs and liver are intricate and complex organic structures composed of varying tissues and cell types. Although bioengineered lungs and livers have been constructed which can survive 2 months in vivo, many obstacles need to be overcome to enhance their longevity for practical purposes.^{15,16} Despite this, bioengineered tissues from decellularized donor organ and MSCs still hold a vital promise in stem cell research.

Despite all the efforts poured in stem cell research, the final goal is to come up with a potential cure of human diseases. The next big question being asked is "How close we are to that goal?" There are various trials going on that have proved that stem cell based therapeutics are not merely a hypothetical concept; but actual results are "Just around the corner".

One such example is cellular therapy for myocardial infarction. Phase II and Phase III clinical trials are underway for intravenous implantation of MSCs for myocardial infarction. This approach has received global applaud because of eminent success of MSCs. MSCs when used in myocardial infarction show very low immunogenicity and have also shown great potential in healing and revascularizing the host tissue. Also these bone marrow derived MSCs have shown no tumorigenesis or MSCs induced/formed micro emboli. Various clinical trials have proven the safety and

efficacy of MSCs use in patients with myocardial infarction as well as for graft versus host disease.^{17,18}

Another noteworthy utilization of stem cells is in Limbal Stem Cell Deficiency (LSCD) of eye which is a common sequel of chemical or thermal injuries to ocular surface. In this pathology, stem cells of limbus are permanently lost from the eye surface, which play a vital role in day to day regeneration of smooth and optically clear corneal surface. As a result, the cornea is opacified and results in permanent blindness which may not be ameliorable to even corneal transplants; because transplanted cornea is also dependent on host limbal stem cells for their survival. Allogeneic limbal stem cells can be harvested from the contralateral uninvolved eye and can be utilized for curing LSCD; thus restoring eye sight.^{19,20}

In the field of neurosciences, Phase I trials of hESCs for spinal cord injuries have been completed by Geron.²¹ They have shown that hESCs derived oligodendrocytes have the potential of remyelination of damaged spinal cord neurons after spinal cord injuries which leave the patient potentially crippled with problems of motor/sensory dysfunction of limbs and bladder. These hESCs derived oligodendrocytes not only lay down new myelin sheath for electric impulse conduction but have also shown to be producing several factors that positively influence the growth and survival of damaged neurons.

Since much of the work of Geron has focused on transplanting hESCs derived oligodendrocytes for spinal cord repair, other research groups have worked on more complex neurodegenerative disorders like Alzheimer's, Huntington's and Parkinson's disease by conceptualizing the idea of recruiting endogenous neurological stem cells residing in the niches of forebrain. Magdalena Gotz has worked on reactive astrocytes and shown that they possess some indigenous neurogenic activity which may be harnessed at the damaged site of the brain; where reactive astrocytes are naturally most abundant.²²

Other success stories of stem cell therapeutics frontier worth mentioning are the harnessing of hESCs for the cure of diabetes and hypothyroidism.^{23,24} In the field of oncology, MSCs are employed to understand and modify tumor behavior.²⁵ Noteworthy breakthroughs in stem cell medicine have also been made in hepatology, orthopaedics and ophthalmology.

It may be beyond the scope of this editorial to credit and applaud all the new and exciting breakthroughs currently happening in stem cell biomedicine frontier that are focused on the singular goal of improving the quality of life of patients currently suffering from diseases that are not treatable with conventional allopathic medicine. Still, I am strongly convinced that stem cell biomedicine is not a mere vague medical

instead, the answers to puzzles heralding stem cell biomedicine actually seem to be “Just around the corner”.

REFERENCES

- Vemuganti GK, Sangwan VS, Rao GN. The promise of stem cell therapy for eye disorders. *Clin Exp Optom*. 2007 Sep;90(5):315-6.
- Armstrong L, Lako M, Buckley N, Lappin TR, Murphy MJ, Nolte JA, Pittenger M, Stojkovic M. Editorial: Our top 10 developments in stem cell biology over the last 30 years. *Stem Cells*. 2012 Jan;30(1):2-9.
- Kleinsmith LJ, Pierce GBJr. Multipotentiality of single embryonal carcinoma cells. *Cancer Res*. 1964 Oct;24:1544-51.
- Evans MJ, Kaufman MH. Establishment in culture of pluripotential cells from mouse embryos. *Nature*. 1981 Jul 9;292(5819):154-6.
- Williams RL, Hilton DJ, Pease S, Willson TA, Stewart CL, Gearing DP, Wagner EF, Metcalf D, Nicola NA, Gough NM. Myeloid leukemia inhibitory factor maintains the developmental potential of embryonic stem cells. *Nature*. 1988 Dec 15;336(6200):684-7.
- Thomson JA, Itskovitz-Eldor J, Shapiro SS, Waknitz MA, Swiergiel JJ, Marshall VS, Jones JM. Embryonic stem cell lines derived from human blastocysts. *Science*. 1998 Nov 6;282(5391):1145-7.
- Takahashi K, Tanabe K, Ohnuki M, Narita M, Ichisaka T, Tomoda K, Yamanaka S. Induction of pluripotent stem cells from adult human fibroblasts by defined factors. *Cell*. 2007 Nov 30;131(5):861-72.
- Park IH, Zhao R, West JA, Yabuuchi A, Huo H, Ince TA, Lerou PH, Lensch MW, Daley GQ. Reprogramming of human somatic cells to pluripotency with defined factors. *Nature*. 2008 Jan 10;451(7175):141-6.
- Brennan KJ, Simone A, Jou J, Gelboin-Burkhart C, Tran N, Sangar S, Li Y, Mu Y, Chen G, Yu D, McCarthy S, Sebat J, Gage FH. Modelling schizophrenia using human induced pluripotent stem cells. *Nature*. 2011 May 12;473(7346):221-5.
- Friedenstein AJ, Piatetzky-Shapiro II, Petrakova KV. Osteogenesis in transplants of bone marrow cells. *J Embryol Exp Morphol*. 1966 Dec;16(3):381-90.
- Caplan AI. Mesenchymal stem cells. *J Orthop Res*. 1991 Sep;9(5):641-50.
- Erices A, Conget P, Minguell JJ. Mesenchymal progenitor cells in human umbilical cord blood. *Br J Haematol*. 2000 Apr;109(1):235-42.
- Zuk PA, Zhu M, Ashjian P, De Ugarte DA, Huang JJ, Mizuno H, Alfonso ZC, Fraser JK, Benhaim P, Hedrick MH. Human adipose tissue is a source of multipotent stem cells. *Mol Biol Cell*. 2002 Dec;13(12):4279-95.
- Macchiarini P, Jungebluth P, Go T, Asnaghi MA, Rees LE, Cogan TA, Dodson A, Martorell J, Bellini S, Parnigotto PP, Dickinson SC, Hollander AP, Mantero S, Conconi MT, Birchall MA. Clinical transplantation of a tissue-engineered airway. *Lancet*. 2008 Dec 13;372(9655):2023-30.
- Uygun BE, Soto-Gutierrez A, Yagi H. Organ reengineering through development of a transplantable recellularized liver graft using decellularized liver matrix. *Nat Med*. 2010;16:814-20.
- Perniconi B, Costa A, Aulino P, Teodori L, Adamo S, Coletti D. The pro-myogenic environment provided by whole organ scale acellular scaffolds from skeletal muscle. *Biomaterials*. 2011 Nov;32(31):7870-82.
- Hare JM, Traverse JH, Henry TD, Dib N, Strumpf RK, Schulman SP, Gerstenblith G, DeMaria AN, Denktas AE, Gammon RS, Hermiller JB Jr, Reisman MA, Schaefer GL, Sherman W. A randomized, double-blind, placebo-controlled, dose-escalation study of intravenous adult human mesenchymal stem cells (prochymal) after acute myocardial infarction. *J Am Coll Cardiol*. 2009 Dec 8;54(24):2277-86.
- Le Blanc K, Frasson F, Ball L, Locatelli F, Roelofs H, Lewis I, Lanino E, Sundberg B, Bernardo ME, Remberger M, Dini G, Egeler RM, Bacigalupo A, Fibbe W, Ringden O; Developmental Committee of the European Group for Blood and Marrow Transplantation Mesenchymal stem cells for treatment of steroid-resistant, severe, acute graft-versus-host disease: A phase II study. *Lancet*. 2008 May 10;371(9624):1579-86.
- Kolli S, Ahmad S, Lako M, Figueiredo F. Successful clinical implementation of corneal epithelial stem cell therapy for treatment of unilateral limbal stem cell deficiency. *Stem Cells*. 2010 Mar 31;28(3):597-610.
- Rama P, Matuska S, Paganoni G, Spinelli A, De Luca M, Pellegrini G. Limbal stem cell therapy and long term corneal regeneration. *N Engl J Med*. 2010 Jul 8;363(2):147-55.
- Keirstead HS, Nistor G, Bernal G, Totoiu M, Cloutier F, Sharp K, Steward O. Human embryonic stem cell-derived oligodendrocyte progenitor cell transplants remyelinate and restore locomotion after spinal cord injury. *J Neurosci*. 2005 May 11;25(19):4694-705.
- Buffo A, Rite I, Tripathi P, Lepier A, Colak D, Horn AP, Mori T, Götz M. Origin and progeny of reactive gliosis: A source of multipotent cells in the injured brain. *Proc Natl Acad Sci USA*. 2008 Mar 4;105(9):3581-6.
- Mfopou JK, Chen B, Sui L, Sermon K, Bouwens L. Recent advances and prospects in the differentiation of pancreatic cells from human embryonic stem cells. *Diabetes*. 2010 Sep;59(9):2094-101.
- Antonica F, Kasprzyk DF, Opitz R, Iacovino M, Liao XH, Dumitrescu AM, Refetoff S, Peremans K, Manto M, Kyba M, Costagliola S. Generation of functional thyroid from embryonic stem cells. *Nature*. 2012 Nov 1;491(7422):66-71.
- Altanerova V, Cihova M, Babic M, Rychly B, Ondicova K, Mravec B, Altaner C. Human adipose tissue-derived mesenchymal stem cells expressing yeast cytosine deaminase: uracil phosphoribosyltransferase inhibit intracerebral rat glioblastoma. *Int J Cancer*. 2012 May 15;130(10):2455-63.



Effect of Internal Limiting Membrane Peeling on Functional and Structural Outcome of Pars Plana Vitrectomy for Rhegmatogenous Retinal Detachment

Haroon Tayyab, Sana Jahangir, Syed Hassan Bin Usman Shah Bukhari, Samina Jahangir and Akhwand Abdul Majeed Jawad

ABSTRACT

Objective: The purpose of this study was to evaluate the effect of internal limiting membrane peeling on visual acuity and structural macular surface anatomy in patients with rhegmatogenous retinal detachment.

Methodology: A total of 20 patients divided in 2 equal Groups A and B comprising of 10 patients each were included in this study. All patients had rhegmatogenous retinal detachment of less than one month duration with minimal or no proliferative retinopathy. Both Groups A and B underwent pars plana vitrectomy and silicone oil / gas tamponade with Group A also undergoing internal limiting membrane peeling as an adjunct to surgery. A minimum of 6 months followup was planned for both groups to evaluate and compare the effect of internal limiting membrane peeling on visual acuity and epiretinal membrane formation at end of 6 months.

Results: At the end of 6 months followup, there was statistically significant difference in pre and post operative visual acuity in both the groups (p-value <0.001). But there was no difference in post operative visual acuity in both groups when evaluated for the effect of internal limiting membrane peeling (p-value = 0.27). Also, the frequency of epiretinal membrane formation in Group A was significantly less when compared to group B.

Conclusion: We did not find ILM peeling as a useful adjunct to retinal reattachment surgery for improving post operative best corrected visual acuity. Although internal limiting membrane peeling had statistically significant results in preventing post operative epiretinal membrane formation. Internal limiting membrane peeling should be reserved for those cases only where epiretinal membrane already exists before retinal reattachment surgery.

Keywords: Retinal detachment. Microincision vitrectomy surgery. Epiretinal membrane. Internal limiting membrane. Proliferative vitreoretinopathy retinopathy.

INTRODUCTION

Retinal surgery has evolved through many stepping stones before it has taken its recent shape with Micro Incision Vitrectomy Surgery (MIVS). MIVS offers faster recovery times and better wound healing to the patient. It has also revolutionised the surgical techniques for more complex cases; especially cases of retinal detachment with advanced grade proliferative vitreoretinopathy and diabetic retinopathy.¹ But restoration of normal anatomy of retina does not ensure perfect visual recovery and patients often complain of decreased contrast sensitivity, distortion of images and reduced visual fields after successful retinal surgery.² Various innovations in techniques of retinal detachment repair have been employed to achieve better visual results apart from getting anatomical success only. One such new technique is to peel off Internal Limiting Membrane (ILM) from macular area during pars plana vitrectomy (PPV). ILM is composed of Muller cell

foot plates, proteoglycans and type IV collagen.² Through our clinical experience, it has been established that presence of ILM can offer a platform for epiretinal membrane (ERM) formation especially after different retinal surgeries as well as after argon laser photocoagulation.³ Removal of ILM has become a standard procedure in various retinal surgeries like macular hole repair surgery and first successful series was reported by Brooks in 2000.^{4,5} Although first case of ILM peeling was reported by Morris in 1990, ILM peeling has become an essential step of PPV for diabetic macular oedema, central retinal vein occlusion and myopic foveoschisis.⁶⁻⁸

Going a step further with ILM peeling, many surgeons now believe that ILM peeling has its place in rhegmatogenous retinal detachment (RRD) with proliferative vitreoretinopathy (PVR). ILM is a rigid structure and it imparts significant stiffness to retinal surface especially in posterior pole diseases.⁹⁻¹⁰

Theoretically, removal of ILM reduces the occurrence of ERM at posterior pole, thus improving the macular structure and function. ILM peeling also reduces retinal surface tension transmitted to macula and offers the mechanical advantage of relaxing the surface tractional forces.¹¹ Also it may provide a plane which can assist in further PVR membrane removal.¹²

Since ILM peeling is a relatively new concept in RRD surgery, it is not well listed in literature because of the

Al-Ehsan Eye Hospital, Shalimar Link Road,
Lahore, Pakistan.

Correspondence: Dr. Haroon Tayyab
Consultant Vitreoretinal Surgeon
Al-Ehsan Eye Hospital
E-mail: haroontayyab79@gmail.com

Received: March 20, 2015; Accepted: June 5, 2015.

long follow ups needed to find the beneficial and harmful effects of ILM peeling on retinal structure and function. With the advent of swept source optical coherence tomography (SS-OCT), long term effects of ILM peeling on macular structure will come into documentation with time as more and more surgeons adapt to this new technique.

The main objective of this study was to evaluate the surgical approach of ILM peeling in RRD and compare the anatomical and functional results with a matched group undergoing retinal reattachment surgery without ILM peeling.

METHODOLOGY

This was a non randomized prospective study conducted Al-Ehsan Eye Hospital, Lahore, Pakistan from June 2014 to November 2014. A total of 20 patients divided into two groups of ten patients each were included in this prospective study. Group A included patients who underwent PPV plus gas/silicone oil tamponade with ILM peeling for RRD; Group B also had matched patients who underwent PPV plus gas/silicone oil tamponade without ILM peeling. Informed consent was taken from all patients and ethical issues concerning this interventional study were discussed with Ethical committee of hospital and appropriate approval was sought. All surgeries were performed under standard operating protocols by single surgeon. A minimum follow up period of 6 months was planned.

All those patients with macula on RRD, Grade C PVR, multiple breaks, giant retinal tears, traumatic retinal detachments, retinal detachments older than one month duration, surgeries requiring retinectomy, second surgery for RRD or any macular pathology (AMD, DME, ERM, macular hole, cystoid macular oedema or macular ischemia) were excluded from this study.

A standard 23G 3 port transconjunctival PPV (TPPV) was performed using Faros Vitrectomy machine (Oertli Instrument AG, Switzerland). All phakic patients also underwent standard phacoemulsification with acrylic

intraocular lens (IOL) implant using 2.7 mm scleral tunnel incision. Phacoemulsification was performed after inserting all 3 cannulas but before switching on infusion. We used Photon xenon light source by Synergetics. Standard surgery for RRD was performed using core and shave settings of vitrectomy machine. Patients in Group A also underwent additional ILM peeling assisted by 0.025% Brilliant Peel dye (Geuder AG, Germany) and ILM peeling forceps (Grieshaber ILM Forceps with Revolution Grip, Alcon Laboratories, Inc., Fort Worth, TX, USA). ILM peeling was performed under Perfluoro Carbon Liquid (PFCL). Silicone oil or C3F8 gas was used as endo tamponade and laser photo coagulation was done around the breaks. Patients were called for follow up on post operative 1st day, 1st week, 1st month and then after 3 months and 6 months and optical coherence tomography (SD-OCT) of macula done at 3 and 6 months interval.

The results of quantitative variables like age, best corrected visual acuity (BCVA) and duration of retinal detachment were expressed as means and standard deviation (SD). Other qualitative variables like gender and presence of post operative ERM was expressed in numbers and frequencies. BCVA was documented using standard LogMAR chart. Independent sample t-test was used to analyze post operative BCVA in Groups A and B. The data from this study was analysed using SPSS v 20.0.

RESULTS

The results for age, gender and duration of retinal detachment are given in Table 1. Mean preoperative BCVA in Group A was 1.28 +/- 0.51 and in Group B, it was 1.24 +/- 0.24. Mean post operative BCVA after 6 months follow up in Group A was 0.53 +/- 0.27 and in Group B was 0.56 +/- 0.22. There was statistically significant difference in preoperative and post operative BCVA of both Group A (p-value <0.001) and Group B (p-value <0.001). But the difference in post operative BCVA between Group A and Group B was statistically not significant (p-value = 0.27).

Table 1

	Group A	Group B
Mean Age +/- SD	53.2 +/- 13.5	47 +/- 13.29
Gender Male % / Female %.	60% / 40%	70% / 30%
Duration of RD in Days	11.20 +/- 6.98	11.3 +/- 7.27
Pre op BCVA in Log MAR	1.28 +/- 0.51	1.24 +/- 0.24
Post op BCVA In Log MAR	0.53 +/- 0.27	0.56 +/- 0.22

The other significant parameter measured between two groups was occurrence of ERM at 6 months followup period. It was found that only one patient (10%) in Group A had post operative ERM as compared to Group B, where 4 patients (40%) had some stage of ERM after 6 months of followup. 3 patients had only cellophane maculopathy that did not effect the quality of vision of patients where as one patient has significant macular pucker that resulted in metamorphosia. It was also noteworthy that 3 out of 4 patients who had post operative ERM had silicone oil (1000cS) in their eyes as tamponade. The single patient of macular pucker in Group B needed second surgery for ERM and ILM peeling at the time of silicone oil removal.

70 % patients in Group A had silicone oil (1000cS) where as rest had intraocular gas (perfluoropropane - C3F8) as endo tamponade. 60% patients in Group B had silicone oil (1000cS) as endo tamponade where as rest had C3F8. Laser photocoagulation was performed only around retinal breaks. 2 patients in each group needed Nd:YAG laser posterior capsulotomy at 5th month post operative period due to visually significant posterior capsular opacification.

We did not include any patient of anatomical failure (unsuccessful retinal reattachment surgery) in final result analysis. Although 1 (10%) one patient in Group A needed second surgery for retinal reattachment with silicone oil tamponade due to progressive PVR. This patient was omitted from final analysis.

DISCUSSION

ERM is an abnormality of vitreoretinal interface effecting visual functions.¹³ ERMs have range of severity; starting from mild cellophane macular reflex to more advanced and visually symptomatic macular pucker. In our study, we did not rank ERM into different grades of severity; all grades were classified ERM as whole.

The second study outcome in our research was visual acuity. Although BCVA is the most reliable visual outcome marker after retinal reattachment surgery, it does not entirely encompasses the wide range of visual functions of retina like contrast sensitivity, colour vision and visual fields.¹⁴

In our study, we did not find statistically significant difference in post operative BCVA between Groups A and B (p-value = 0.27) at 6 months follow up. The additional intervention of removing ILM in Group A did not produce better BCVA than Group B. Although we did not examine the patients for other visual functions as mentioned above.

Shocket reported that post retinal reattachment BCVA is highly dependent on the duration of retinal detachment because longer standing retinal detachments lead to photoreceptor atrophy and Muller

cell hypertrophy which are associated with poorer visual outcomes.¹⁵ Also it has been shown in various studies that maximum amount of photoreceptor death has already happened by second day of retinal detachment.¹⁶ Since average number of days between retinal detachment and its repair in our study was 11.20 +/- 6.98 in Group A and 11.3 +/- 7.27 in group B, we can assume that degree of visual acuity improvement is highly dependent on duration of retinal detachment. A very interesting finding reported by Shocket was that some degree of photoreceptor atrophy also ensues even when there is no macular involvement (macula on) at the time of retinal reattachment surgery. Other parameters very important for predicting prognosis of vision after RD surgery include the preservation of ellipsoid zone and external limiting membrane (ELM) pre and post operatively.¹⁷

Our BCVA results were comparable to Pietras-Trzpiel who also showed no significant difference in BCVA with and without ILM peeling for retinal reattachment surgeries. The difference between our and their study was that they used indocyanine green (ICG) as a staining agent for ILM where as we used Brilliant Peel which is less toxic to retinal layers when used for ILM staining.² Also the rate of post operative ERM formation in ILM peeling group was less than the other group. These results were also in coherence with our study. The difference was that they included patients with preoperative ERM where as we did not include any patient with preoperative ERM in either of the groups; still the occurrence of ERM in non ILM peeling groups was statistically significant when compared to ILM peeling groups. Minarcik also showed in his study of 14 patients that ILM peeling is an effective adjunct to achieving better anatomic and structural results in cases of retinal reattachment surgery, but he did not have a control group and did not comment on improved visual results with ILM peeling.¹²

In contrast to our results, the author of Silicone Study Reports concluded that there is a significant difference in BCVA for patient undergoing ILM peeling during retinal reattachment surgery when compared to controlled group. But this difference was probably due to the fact that SSR group performed ILM peeling in only those patients who had preoperative ERM and not other wise. Therefore, ILM peeling may have a role in ensuring better BCVA in cases of preoperative posterior pole PVR but not other wise.¹⁸ They also did not report the occurrence the post operative ERM in the non ILM peeling group.

Kiss found that ERM develops in 20.5% of patients with complicated retinal detachment treated with PPV and silicone oil tamponade where as our study showed that 40% of patients had ERM postoperatively who did

not under go ILM peeling during surgery.

In our study, one patient needed reoperation at 6th month followup because of macular pucker. He had moderate improvement in BCVA after removal of ERM and ILM peeling. One patient in Group A had failed retinal surgery and his results were omitted from final analysis. We did not encounter any significant per operative and short term post operative complications apart from those mentioned above.

The weakness of this study lies in the fact that we did not evaluate any other visual functions apart from BCVA like contrast sensitivity, colour vision and visual fields since these parameter can also have significant impact on the post operative quality of vision of patients. Also, we did not examine macular and foveal microstructure details like morphology of ellipsoid zone pre and post operatively, status of inner segment and outer segment anatomy and preservation of ELM. We also needed to examine the role of ILM peeling on these structures.

The strength of this study lies in its case control design with matched groups having nearly identical nature of retinal detachments. We also did not include RDs with advanced grades of PVR and long standing RDs which can negatively effect the final BCVA. We also had a reasonable follow up period to asses long term out comes of our intervention.

CONCLUSION

As a conclusion, we did not find ILM peeling as a useful adjunct to retinal reattachment surgery for improving BCVA. Although ILM peeling had statistically significant results in preventing post operative ERM formation, even in patients who developed ERM in control group, it did not have significant effects on final BCVA. Therefore we recommend that ILM peeling during retinal reattachment surgery should be reserved for those cases only where preoperative ERM exists. But, we also did not report any harmful effects of ILM peeling. Certain investigations need to be performed like 10-2 visual fields and swept source OCT to evaluate the effects of ILM peeling in patients with retinal detachment and minimal or no PVR.

1.

REFERENCES

1. Yamada K, Maeno T, Yamada M. Hybrid microincision vitrectomy surgery combined with 20-gauge silicone cannulas for use with 20-gauge horizontal scissors in diabetic tractional retinal detachment. *Clin Ophthalmol.* 2013; 7:1559-63.
2. Pietras-Trzpiel M, Oleszczuk A, Brzozowska A, Forlini C, Juńemann A, Rejda R. Assessment of Visual Function in Patients with Retinal Detachment after Vitrectomy with and without ILM Peeling. *J Clin Exp Ophthalmol.* 2014; 5(3):1-6.

3.

- Mitchell P, Smith W, Chey T, Wang JJ, Chang A. Prevalence and associations of epiretinal membranes. *The Blue Mountains Eye Study, Australia. Ophthalmology.* 1997 Jun; 104(6):1033-40
4. Thompson JT. The effect of internal limiting membrane removal and indocyanine green on success of macular hole surgery. *Trans Am Ophthalmol Soc.* 2007 Dec; 105: 198-206.
5. Brooks HL Jr. Macular hole surgery with and without internal limiting membrane peeling. *Ophthalmology.* 2000 Oct; 107(10):1939-48.
6. Robaszekiewicz J, Chmielewska K, Figurska M, Wierzbowska J, Stankiewicz A. Triple therapy: Phaco-vitrectomy with ILM peeling, retinal endophotocoagulation and intraoperative use of Bevacizumab for diffuse diabetic macular edema. *Med Sci Monit.* 2012 Apr; 18(4):241-51.
7. Baharivand N, Hariri A, Javadzadeh A, Heidari A, Sadegi K. Pars plana vitrectomy and internal limiting membrane peeling for macular edema secondary to retinal vein occlusion. *Clin Ophthalmol.* 2011; 5: 1089-93.
8. Kwok AK, Lai TY, Yip WW. Vitrectomy and gas tamponade without internal limiting membrane peeling for myopic foveoschisis. Vitrectomy and gas tamponade without internal limiting membrane peeling for myopic foveoschisis. *Br J Ophthalmol.* 2005 Sep; 89(9):1180-3.
9. Odrobina DC, Michalewska Z, Michalewski J, Nawrocki J. High-speed, high-resolution spectral optical coherence tomography in patients after vitrectomy with internal limiting membrane peeling for proliferative vitreoretinopathy retinal detachment. *Retina.* 2010 Jun; 30(6):881-6.
10. Sayanagi K, Ikuno Y, Tano Y. Tractional internal limiting membrane detachment in highly myopic eyes. *Am J Ophthalmol.* 2006 Nov; 142(5):850-2.
11. Aras C, Arici C, Akar S, Müftüoğlu G, Yolar M, Arvas S, Baserer T, Koşluoğlu N. Peeling of internal limiting membrane during vitrectomy for complicated retinal detachment prevents epimacular membrane formation. *Graefes Arch Clin Exp Ophthalmol.* 2009 May; 247(5): 619-23.
12. Minarcik JR, Fricken MA. Virtual retinectomy: Indocyanine green-assisted internal limiting membrane peeling as a surgical adjunct in repair of recurrent rhegmatogenous retinal detachment due to PVR. *Clin Ophthalmol.* 2012; 6: 631-6.
13. Nazari H, Dustin L, Heussen FM, Sadda S, Rao NA. Morphometric spectral-domain optical coherence tomography features of epiretinal membrane correlate with visual acuity in patients with uveitis. *Am J Ophthalmol.* 2012 Jul; 154(1):78-86.
14. van de Put MAJ, Hoeksema L, Wanders W, Nolte IM, Hooymans JMM, Los LI. Postoperative Vision-Related Quality of Life in Macula-Off Rhegmatogenous Retinal Detachment Patients and its Relation to Visual Function. *PLoS One.* 2014 Dec 2; 9(12):e114489.
15. Schocket LS1, Witkin AJ, Fujimoto JG, Ko TH, Schuman JS, Rogers AH, Bauman C, Reichel E, Duker JS. Ultrahigh-resolution optical coherence tomography in patients with

16. decreased visual acuity after retinal detachment repair. *Ophthalmology*. 2006 Apr;113(4):666-72.
Arroyo JG, Yang L, Bula D, Chen DF. Photoreceptor apoptosis in human retinal detachment. *Am J Ophthalmol*. 2005 Apr;139(4):605-10.
17. Wakabayashi T, Oshima Y, Fujimoto H, Murakami Y, Sakaguchi H, Kusaka S, Tano Y. Foveal microstructure and visual acuity after retinal detachment repair: Imaging analysis by Fourier-domain optical coherence tomography. *Ophthalmology*. 2009 Mar;116(3):519-28.
18. Cox MS, Azen SP, Barr CC, Linton KL, Diddie KR, Lai MY, Freeman HM, Irvine A. Macular pucker after successful surgery for proliferative vitreoretinopathy. *Silicone Study Report 8*. *Ophthalmology*. 1995 Dec;102(12):1884-91.



The Frequency of Carcinoma Breast in Female Patients who Present with Blood Stained Nipple Discharge

Sidra Dil Muhammad, Muhammad Saad Faisal, Faiza Siddique,
Ahsen Nazir Ahmed, Hira Mirza and Sadia Javaid

ABSTRACT

Objective: To calculate frequency of carcinoma breast in female patients presenting with blood stained nipple discharge.

Methodology: This cross sectional study was conducted at Sir Ganga Ram Hospital Lahore, from 13th June to 12th December 2011. The objective was to calculate the frequency of carcinoma breast in females presenting with blood stained nipple discharge. Seventy patients presenting with blood stained nipple discharge were included in the study and diagnosed on the basis of cytological examination.

Results: The result was categorised as positive (carcinoma breast) or negative (benign breast lesion). The mean age of patients was 41.2 ± 10.9 years. In this study, we found that 31.4% patients had positive and 68.6% patients had negative cytology. There were 31.4% patients who had carcinoma of breast.

Conclusion: The frequency of carcinoma of breast among patients with nipple discharge was higher than lump in the breast expected in this study population. It was found that 31.4% of patients has carcinoma breast and all of these patients tested positive for cytology.

Key Words: Blood stained nipple discharge. Lump breast. Carcinoma breast.

INTRODUCTION

Among carcinoma breast, two main types are the ductal carcinoma and the lobular carcinoma.¹ Infiltrative ductal carcinoma and infiltrative lobular carcinoma account for more than 90% of all invasive breast cancers.² Infiltrative ductal carcinoma is the commonest histological variant.^{3,4} Breast cancer is the most common cancer in women.⁵ It is the second most common cause of cancer death in women.⁶ The incidence is 10.9% of all the cancers amongst women worldwide.⁷ The largest number of cases are seen between 30-39 years of age.⁸ The most frequent clinical presentation of breast carcinoma is palpable mass (92.1%), nipple discharge (5.3%) and clinically occult lesion diagnosed on mammography (2.6%).⁹ Other main complaints are nipple retraction, pain, fungation and ulceration of skin.¹⁰ Left breast is more commonly involved.¹¹

METHODOLOGY

Patients having blood stained nipple discharge and palpable lump had cytological examination of discharge and the lump and if malignant cells were

found in both the samples, patients were diagnosed as having breast carcinoma. This study was conducted in General Surgery Department of Sir Ganga Ram Hospital Lahore from 13th June to 12th December 2011. This cross sectional study had a sample size of 70 cases with confidence interval (CI) of 95%. With non probability purposive sampling, the patient aged 25-60 years with blood stained nipple discharge were included in study. Females with history of watery and serous discharge, nipple trauma and bleeding disorders were excluded. Informed consent was taken and relevant performa was developed. All the patients were referred to histopathology department of Sir Ganga Ram Hospital for cytological examination of the discharge. The cytology smear was prepared and commented by a Fellow of Pathology, who had at least 5 years experience in field of pathology. The results were categorised as blood stained nipple discharge positive (carcinoma breast) or negative (benign breast lesion).

The data was entered in SPSS version 20.0 and analysed accordingly. Study variables were analyzed by simple descriptive statistics. Mean and standard deviation was calculated for numerical variables. Informed consent was obtained from all participants of this study and study design was approved by Hospital Ethical Committee.

RESULTS

The mean age of the patients was 41.2 ± 10.9 years and distribution according to age range is shown in Table 1.

Sharif Medical & Dental College, Sharif Medical City,
Sharif Medical City Road, Off Raiwind Road, Jati Umra,
Lahore 54000, Pakistan.

Correspondence: Dr. Sidra Dil Muhammad
Assistant Prof. Department of Surgery
Sharif Medical & Dental College
E-mail: sirdradilmuhammad@hotmail.com

Received: March 16, 2015; Accepted: May 27, 2015.

Table 1: Distribution of patients by age (n=70)

Age (Years)	No. of Patients	Percentage
25-30	14	20.0
31-40	28	40.0
41-50	18	25.7
51-60	10	14.3
Mean \pm SD	41.2 \pm 10.9	

n: Number of patients
SD: Standard Deviation

Table 2: Distribution of patients by malignant cells on cytological examination of nipple discharge (n=70)

Malignant cells	No. of Patients	Percentage
Yes	22	31.4
No	48	68.6
Total	70	100.0

n: Number of patients

22 (31.4%) patients resulted positive for nipple discharge and 48 (68.6%) patients had negative results (Table 2).

Amongst patients with breast lump, 22 (31.4%) tested positive for malignant cell and 48 (68.6%) were negative for malignant cell.

Montroni, in one study, had reported that cancer is present in 18% of patients with watery nipple discharge. Cancer was detected in 100 (30.3%) patients with bloody nipple discharge and in 42 (17.6%) patients with serous discharge.¹²

DISCUSSION

Breast cancer is the leading cause of death in women. In Pakistan, the prevalence of carcinoma of breast is 9 in 100 females.¹³ Investigation of nipple discharge includes triple assessment which consists of physical, radiological examination and biopsy.¹⁴ Treatment offered is based on triple assessment and ranges from lumpectomy to total mastectomy depending on the stage of disease.¹⁵ The overall five year survival rate is 63%.¹⁶

In this study, the mean age of the patients was 41.2 \pm 10.9 years. In comparison to study of Wong, the mean age of the patients was 43 years.¹⁷ Krishnamurthy reported the mean age of the patients to be 54 years.¹⁸ So, there was a great variation in mean age of the patients who presented with blood stained nipple discharge. This might be due to the variation in geographic or genetic variation among different populations across the globe. In the current study, the frequency of carcinoma and the patients with nipple discharge tested positive were 31.4% as compared to Richards, in which these were reported to be 40% and

47% respectively.¹⁹

So, it can be observed that frequency of carcinoma of the breast was lower among our population. Approximately, one third of the patients suffered from carcinoma. Usually, the blood stained nipple discharge is taken as a result of infection or due to benign conditions. Moreover, in absence of any palpable mass, it is ignored and is treated on the basis of infectious aetiology. In this area of low resources, and poor socioeconomic status, where poverty and ignorance is very common, it is required to educate the primary physicians to routinely use the cytology examination of nipple discharge. This simple test is safe, non invasive and can be performed in remote areas where the facilities of breast cancer surgeons or modern pathology laboratories are not available. Nipple discharge cytology is specific in cases of malignancy but is often inadequate for routine assessment.²⁰

There were a few limitations of the study. This was a single center study with limited population size. This study was not a representative of the whole population.

CONCLUSION

It is concluded from our study that blood stained nipple discharge in a patient with breast lump is a strong indicator for breast carcinoma. We strongly recommend that the patients with blood stained nipple discharge should undergo discharge cytology as first line investigation.

REFERENCES

1. Carlson RW, Allred DC, Anderson BO, Burstein HJ, Carter WB, Edge SB, Erban JK, Farrar WB, Goldstein LJ, Gradishar WJ, Hayes DF, Hudis CA, Jahanzeb M, Kiel K, Ljung BM, Marcom PK, Mayer IA, McCormick B, Nabell LM, Pierce LJ, Reed EC, Smith ML, Somlo G, Theriault RL, Topham NS, Ward JH, Winer EP, Wolff AC. Breast cancer clinical practice guidelines in oncology. *J Natl Compr Canc Netw*. 2009 Feb;7(2):122-92.
2. Chikman B, Lavy R, Davidson T, Wassermann I, Slegelmann-Danieli N, Halevy A. Factors affecting rise in incidence of infiltrating lobular carcinoma of breast. *Isr Med Assoc J*. 2010 Nov;12(11):697-700.
3. Aslam MN, Ansari AK, Siddique A, Imran M. Carcinoma of breast, late presentation –A big concern. *Ann King Edward Med Coll*. 2006;12:317-9.
4. Alwan NA. Breast cancer: Demographic characteristics and clinico-pathological presentation of patients in Iraq. *East Mediterr Health J*. 2010 Nov;16(11):1159-64.
5. Ghorbel I, Kanoun S, Kallel A, Belaid A, Azoury F, Heymann S, Pichenot C, Verstraet R, Marsiglia H, Bourgier C. Early breast cancer without axillary lymph node involvement. *Cancer Radiother*. 2010 Nov; 14 Suppl1:S127-35.
6. Jhan AK, Hamal PK, Jha J, Banthia P, Thakali K, Basne BK. Pattern of breast cancer in a tertiary care center. *JNMA J Nepal Med Assoc*. 2010 Jan-Mar;49(177):1-5.
7. Aziz A, Javed SM, Shuaib M, Jafari GA, Manzar S. Bilateral carcinoma breast. *Pak J Surg*. 2005;21:109-11.
8. Khanum A, Khan AZ, Nazir A, Saleem M, Bhutta AR, Abid KJ. Social aspect of patient with carcinoma breast presented in Sir Ganga Ram Hospital, Lahore. *Ann King Edward Med Uni*. 2004;10:126-7.
9. Kayani N, Bhurgri Y. Ductal carcinoma in situ (DCIS) in Karachi. *J Pak Med Assoc*. 2005 May;55(5):199-202.
10. Qureshi JN, Qureshi ZA, Arm P, Memon AS. Evaluation of breast cancer in breast lumps. *J Surg Pak*. 2001;6:7-9.
11. Kocic B, Filipovic S, Petroic B, Mijalkoic D, Rancic N, Poultsidi A. Clinical and biological characteristics of breast cancer. *J BUON*. 2010 Oct-Dec;15(4):660-7.
12. Montroni I, Santini D, Zucchini G, Fiacchi M, Zanti S, Ugolini G. Nipple discharge: Is its significance as a risk factor for breast cancer fully understood? Observational study including 915 consecutive patients who underwent selected duct excision. *Breast Cancer Res Tret*. 2010;123:895-900.
13. Prevalence and incidence of breast cancer; National mortality database, Australia's health 2004. Available from: <http://www.wrongdiagnosis.com/b/breast-cancer/prevalence.htm>
14. Ahmad I, Nazir R, Chaudhary MY, Kundi S. Triple assessment of breast lump. *J Coll Physicians Surg Pak*. 2007 Sep;17(9):535-8.
15. Bray F, McCarron P, Parkin DM. The changing global patterns of female breast cancer incidence and mortality. *Breast Cancer Res*. 2004;6(6):229-39.
16. Aphinives P, Puchai S, Vajirodom D, Bhudhisawasdi V. Breast cancer: Five year survival in Srinagarind Hospital, Thailand. *J Med Assoc Thai*. 2010 Mar;93 Suppl 3:S25-9.
17. Wong L, Chung YF, Wong CY. Microdochectomy for single-duct nipple discharge. *Ann Acad Med Singapore*. 2000 Mar;29(2):198-200.
18. Krishnamurthy S, Sneige N, Thompson PA, Marcy SM, Singletary SE, Cristofanilli M, Hunt KK, Kuerer HM. Nipple aspirate fluid cytology in breast carcinoma. *Cancer*. 2003 Apr 25;99(2):97-104.
19. Richards T, Hunt A, Courtney S, Umeh H. Nipple discharge: A sign of breast cancer? *Ann R Coll Surg Engl*. 2007 Mar;89(2):124-6.
20. Gupta RK, Gaskell D, Dowle CS, Simpson JS, King BR, Naran S, Lallu S, Fauck R. The role of nipple discharge cytology in the diagnosis of breast disease: A study of 1948 nipple discharge smears from 1530 patients. *Cytopathology*. 2004 Dec;15(6):326-30.



Efficacy of Percutaneous Trigger Finger Release

Farooq Azam Khan, Waqas Ali and Syed Saqib Raza

ABSTRACT

Objective: To determine the efficacy of percutaneous surgical release in patients of trigger finger for resolution of the pre operative symptoms of the involved digit at 6 weeks post operative follow up.

Methodology: One hundred and fifty patients of either gender presenting with trigger finger above 18 years of age were included in the study. This descriptive study started after approval from the ethical committee of Jinnah Hospital Lahore. All patients were treated on out-patient program by the consultants. Eighteen gauge needle was used to release the A1 pulley. The procedure was done under local anaesthesia. Three follow up visits were done at 2 weeks interval. At the end of 6th week, final assessment was done for resolution of symptoms and pain free range of motion.

Results: The mean age of patients was 42.8 ± 11 years (Mean \pm SD). In the gender distribution, 127 patients were females and 23 were males. Half (50%) of the patients presented with locking and stiffness of finger; ring finger being the most common (66%). Clinical outcome of 139 (92.6%) patients showed full range of motion and resolution of symptoms at 6 weeks after intervention.

Conclusion: Percutaneous release of A1 pulley is an effective treatment of trigger finger patients.

Key words: Trigger finger. First annular pulley. Percutaneous release.

INTRODUCTION

Trigger finger is narrowing of flexor tendon sheath and is a relatively common problem. This leads to constriction entrapment of the flexor digitorum superficialis or flexor digitorum profundus tendons.¹

It is mostly seen in middle aged women especially diabetics and postmenopausal.²⁻⁶ Ring finger, middle finger and thumb are commonly involved. Its etiology is still controversial; however nodular thickening of the tendon or constriction of tendon sheath may cause this condition.⁷⁻¹⁰ Trauma, irritation and inflammation causes swelling or nodular thickening of tendon.^{11,12} It can also occur due to overuse of the mentioned muscle.¹³ It can involve more than one finger of same hand or both hands.¹⁴

Patient usually presents with stiffness, pain, swelling, inability to move finger (locking), snapping sound and passive assistance in extension of flexed finger. Diagnosis of trigger finger is made on clinical examination.¹

There are three treatment modalities for trigger finger patients including steroid injections, splinting and surgical release.¹⁵⁻¹⁸

Steroid injection is a temporary remedy and recurrence may occur. Complications like skin depigmentation, fat atrophy and spontaneous rupture of the flexor tendons can occur due to steroid injections.¹⁹⁻²¹

Usually, splinting is also not successful as it is a time consuming treatment and the splint should be worn 24 hours a day for 3-6 weeks.^{5,22}

Surgery is widely regarded as the best treatment option, as it has fewer complications and less chances of recurrence.^{17,23} Surgical release can be performed by open or percutaneous method.²⁴ The annular A1 pulley is released over the metacarpophalangeal joint.²⁵ Open surgical release provides greater exposure and chances of iatrogenic neurovascular injury are minimal.²⁶ Various studies have shown its success rates ranging from 90% to 100% proving the efficacy of this procedure.^{27,28} Overall, complication rates may be slightly higher than the percutaneous release.²⁹ They include reflex sympathetic dystrophy, infection, stiffness, nerve transection, incision pain, flexion deformity, flexor tendon bowstringing, and recurrence (3%).³⁰

Percutaneous surgical release gives quick and definitive relief from this condition.³¹⁻³³ It is a simple and safe procedure. It requires less time and results in fewer complications.^{8,30,34} A recent study showed that percutaneous release of A1 pulley resulted in complete resolution of the symptoms in 45 (90%) out of 50 patients.²³ Another study showed that 314 (92.90%) out of 338 digits which were treated with percutaneous release recovered full range of motion of the affected digits when followed up to 6 weeks after procedure.²²

Sharif Medical & Dental College, Sharif Medical City,
Sharif Medical City Road, Off Raiwind Road, Jati Umra,
Lahore 54000, Pakistan.

Correspondence: Dr. Farooq Azam Khan
Assistant Prof. Department of Orthopaedics
Sharif Medical & Dental College
E-mail: dr.farooq224@hotmail.com

Received: March 16, 2015; Accepted: June 13, 2015.

The rationale of this study is to determine the efficacy of percutaneous release of trigger finger in terms of resolution of symptoms and recovery of full range of motion. Although various international studies are available but there is no local data available to highlight the efficacy of this cost effective and less time consuming procedure.

METHODOLOGY

It was a descriptive study, carried out at Department of Orthopaedics, Allama Iqbal Medical College, Jinnah Hospital Lahore. Sample size of 150 cases was calculated with 95% confidence level, 5% margin of error and taking expected percentage of efficacy in terms of resolution of symptoms and full range of motion i.e. 90% of percutaneous surgical release in patients of trigger finger.

Inclusion Criteria

All patients of either gender presenting with trigger finger above 18 years of age

Exclusion Criteria

- Patients already treated for trigger finger through other modalities.
- Patients having any superficial or deep skin infections diagnosed on history and examination.
- Patients with united, mal-united or non-united fractures around the wrist diagnosed on history, examination and X-ray of wrist joint.
- Patients with history of surgery on tendons or blood vessels around the wrist.
- Diagnosed patients with gout and osteoporosis.
- Patients presenting with ruptured flexor tendons.

An approval from ethical committee of hospital was taken. Patients presenting in outdoor patient department fulfilling the inclusion criteria were selected. Informed consent was taken and history proforma was filled. All cases were operated by a single consultant on day care basis.

Aseptic technique was used. Metacarpophalangeal (MCP) joint and the site of A1 pulley was identified and marked. Local anaesthesia (lignocaine 2%) was infiltrated around the site with an insulin syringe. Preparation of the involved hand was done by standard scrub procedure. The involved digit was hyperextended and kept in the position with the help of assistant. Eighteen gauge sterilized needle was used in the procedure.

The needle was inserted perpendicularly onto the A1 pulley at the MCP joint and was moved proximal to the distal site. Free mobility of the finger was checked after the procedure on the table.

After the procedure small sterile dressing was applied on needle entry site.

All patients followed a uniform regimen of physiotherapy that started immediately in the post operative period and were assessed at 1st post operative day. Three follow ups were performed at every two weeks interval. Improvement was labeled at the end of 6 weeks with the achievement of resolution of preoperative symptoms and pain free range of movements. All the collected data was entered & analyzed by SPSS version 20.

RESULTS

The mean age of the sample was 42.8 ± 11 years (Mean \pm SD), with the youngest patient being 25 years and oldest at 66 years. The distribution of patients according to age is depicted in Figure 1.

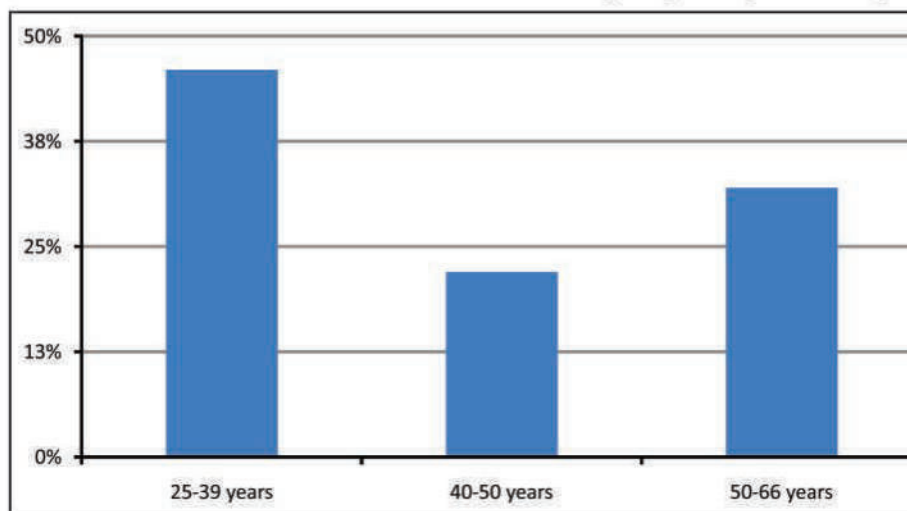


Figure 1: Distribution of patients according to age

In the gender distribution, 127 patients were females and 23 patients were male. Mean age of female patients was 42 ± 11.6 years whereas the mean age of male patients was 46.9 ± 7.2 years.

Patients presented with stiffness, pain, swelling, inability to move finger (locking), snapping sound with above 50% presenting with locking and stiffness. Out of 150 patients, clinical outcome of 139 (92.6%) patients showed full range of motion and resolution of

symptoms at 6 weeks while 11 (7.3%) patients showed partial range of motion and persistence of symptoms. Results are depicted in Figure 2 and 3.

The most commonly involved finger was ring finger (66%), followed by middle and index finger. Only four patients have more than one trigger finger (2.6%) as shown in Table 1.

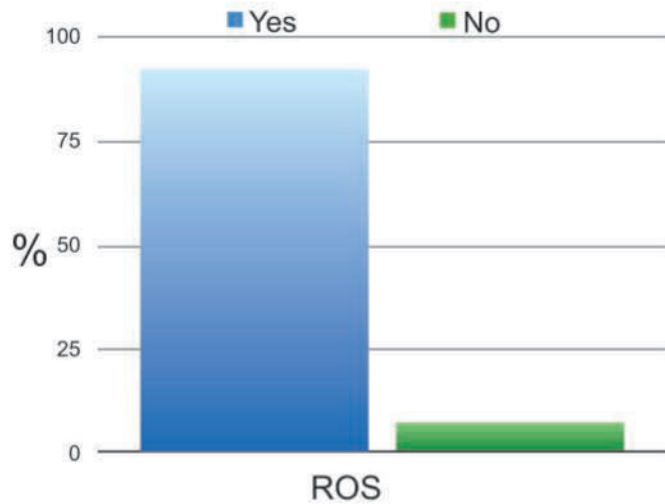


Figure 2: Showing resolution of symptoms (ROS)

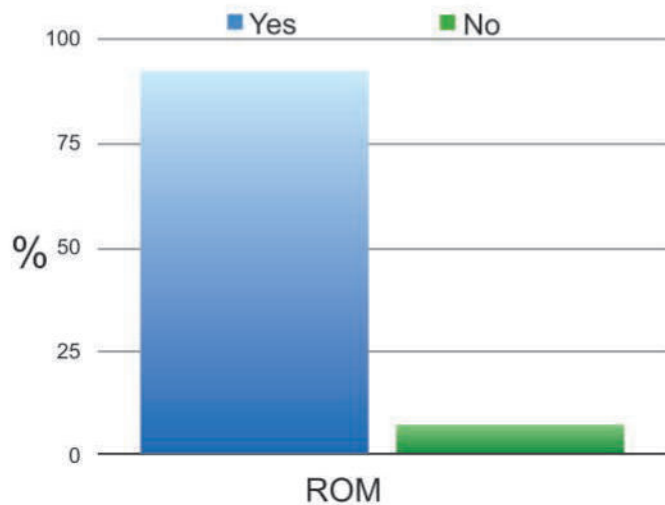


Figure 3: Showing range of motion (ROM) after percutaneous release of A1 pulley

Table 1: Finger involvement

Finger	Frequency	Percent	Valid Percent	Cumulative Percent
Index	10	6.7	6.7	6.7
Middle	31	20.7	20.7	27.3
2,3	2	1.3	1.3	28.7
Ring	99	66.0	66.0	94.7
3,4	2	1.3	1.3	96.0
Little	6	4.0	4.0	100.0
Total	150	100.0	100.0	-

DISCUSSION

Trigger finger is a common problem that mainly affects middle aged women. It frequently requires treatment and various treatment modalities are available. Percutaneous release of A1 pulley is being increasingly used as an alternative to open surgical release and steroid injections. In this study we performed percutaneous release in the outdoor patient department (OPD) as a minor procedure. Patients were assessed at the end of 6th weeks after intervention in terms of resolution of symptoms and pain free range of motion.

In this study 127 patients were females and 23 patients were male. The most commonly involved finger was ring finger (66%) followed by middle and index finger. So the incidence of trigger finger is high in females and ring finger is commonly involved. Comparable results were shown in a study carried out in USA. According to them trigger finger is 6 times more common in females than in males and the most commonly involved digit was ring finger.¹⁹

According to our study the mean age for the sample was 42.8 ± 11 (Mean \pm SD), with the youngest patient being 25 years of age and oldest 66 years. However various studies showed that trigger finger is more common in patients above 50 years.^{1,23}

This study also showed that the mean duration of symptoms ranged from 6 months to 1 year. Similar results were found in another study carried out in United Kingdom. According to this study mean duration of pre-operative symptoms was 7.3 months.²⁴

Our results showed that out of 150 patients, 139(92.6%) showed complete resolution of symptoms and pain free active range of motion in 6 weeks.

Bain and Wallwork conducted a study in Australia in which 31 cases of trigger finger were evaluated and managed. A percutaneous release was performed with a 14-gauge intravenous catheter needle under local anaesthesia in the outdoor patient department. Only one case had incomplete release of A1 pulley. There were no digital nerve injuries, flexor tendon injuries, bowstringing or infections. All the patients had no pain at the operative site, and their preoperative range of motion had returned or improved in two months.

According to them 97 % patients have improved significantly following trigger finger release.³³

A study conducted in Poland compared the results of percutaneous A1 pulley release and steroid injection in 95 patients. Patients after percutaneous release had less pain on movement of the involved digit, but lower active range of motion of the fingers. They concluded that percutaneous A1 pulley release is more effective therapy for trigger finger than steroid injection, because of lower risk of recurrence.³⁵

A recent study conducted showed that percutaneous trigger finger is safe and effective. Percutaneous release of the A1 pulley was done by a 15 guage blade. This study showed that 72% of the patients had complete release of the A1 pulley. They also concluded that this method is safe.³⁶

Another study carried out in United Kingdom showed almost similar results as our study. This study also showed that percutaneous release is safe and effective treatment. The A1 pulley was sectioned by a specially designed blade which has a hooked end. Percutaneous release of 185 trigger fingers was performed by this knife. Satisfactory results were achieved in 173 (93.5%). There were no significant complications. This study also showed that percutaneous trigger finger release is effective out patient procedure for those who have not responded successfully to conservative treatment, have longstanding symptoms or severe triggering.³⁷

Blumberg, used 18 guage needle for the percutaneous release of trigger finger. Twenty nine patients with 31 trigger digits were treated by percutaneous release under local anaesthesia in outdoor patient department. Twenty seven patients (93.7%) with 29 trigger digits had complete relief of their symptoms.³⁸

Rafee concluded that percutaneous trigger finger release was satisfactory procedure in terms of immediate effect on abolishing triggering patient and acceptance was excellent. They reported 97% success rate.³⁹

Another study compared the results of percutaneous release with open surgical technique for trigger fingers. Operation time, duration of postoperative pain,

recovery of motor function, and surgical complications were assessed. Trigger digits were successfully treated in 100% of the cases using the percutaneous technique. Mean duration of postoperative pain and time to recovery of motor function were significantly shorter for patients treated with the percutaneous method. No serious complications were seen in either group.⁴⁰

The limitation of this study is its short duration of 6 months with a follow up time of 6 weeks. Although the resolution of symptoms and range of motion can be well assessed in the first 6 weeks, but the long term follow up for recurrence of trigger finger should be done. Therefore a long term study is needed to assess the recurrence of trigger finger.

As trigger finger is a common problem in Orthopaedics, percutaneous trigger finger should be done in outdoor patient setting. It is a minor and cost effective procedure with very few reported complications. Its safety, however, can be further increased with the help of ultrasonography. Another study carried out in New York concluded that ultrasound assisted percutaneous release of A1 pulley increased the safety of this procedure by saving neurovascular bundle and flexor tendons.⁴¹ This should be implicated in future clinical practice.

CONCLUSION

Percutaneous surgical release is an effective treatment modality for trigger finger patients. It is safe and cost effective. It results in resolution of the pre operative symptoms and full range of motion of the involved digit. It should be practiced as an outdoor procedure for this common problem.

REFERENCES

1. Makkouk AH, Oetgen ME, Swigart CR, Dodds SD. Trigger finger: Etiology, evaluation and treatment. *Curr Rev Musculoskelet Med.* 2008 Jun;1(2):92-6.
2. Wiwanitkit S, Wiwanitkit V. Trigger digits and diabetes mellitus. *N Am J Med Sci.* 2012 Mar;4(3):117-9.
3. Koh S, Nakamura S, Hattori T, Hirata H. Trigger digits in diabetes: Their incidence and characteristics. *J Hand Surg Eur Vol.* 2010 May;35(4):302-5.
4. Rottgers AS, Lewis D, Wollstein AR. Concomitant presentation of carpal tunnel syndrome and trigger finger. *J Brachial Plex Peripher Nerve Inj.* 2009 Aug 25;4:13.
5. Ray S, Datta AK, Sinhamahapatra P, Ray I, Mukhopadhyay P, Dasgupta S. Prevalence of rheumatic conditions in patients with diabetes mellitus in a tertiary care hospital. *J Indian Med Assoc.* 2011 Feb;109(2):74-8.
6. Marcus AM, Culver JE Jr, Hunt TR 3rd. Treating trigger finger in diabetics using excision of the ulnar slip of the flexor

- digitorum superficialis with or without A1 pulley release. *Hand (NY).* 2007 Dec;2(4):227-31.
7. Yavari M, Hassanpour ES, Mosavizadeh MS. Multiple trigger fingers in a musician: A case report. *Arch Iran Med.* 2010 May;13(3):251-2.
8. Notta A. Recherches sur une affection particuliere des gaines tendineuses de la main. *Arch Gen Med.* 1850;24:142.
9. Flatt AE. Notta's nodules and trigger digits. *Proc (Bayl Univ Med Cent).* 2007 Apr;20(2):143-5.
10. Zychowicz ME. A closer look at hand and wrist complaints. *Nurse Pract.* 2013 Mar 10;38(3):46-53.
11. Castellanos J, Muñoz-Mahamud E, Dominguez E, Del Amo P, Izquierdo O, Fillat P. Long-term effectiveness of corticosteroid injections for trigger finger and thumb. *J Hand Surg Am.* 2015 Jan;40(1):121-6.
12. Harb Z, Bismil Q, Ricketts DM. Trigger finger presenting secondary to leiomyoma: A case report. *J Med Case Rep.* 2009 May 8;3:7284.
13. Colbourn J, Heath N, Manary S, Pacifico D. Effectiveness of splinting for the treatment of trigger finger. *J Hand Ther.* 2008 Oct-Dec;21(4):336-43.
14. Pavlicný R. Percutaneous release in the treatment of trigger digits. *Acta Chir Orthop Traumatol Cech.* 2010 Feb;77(1):46-51.
15. Saeed Banadaky SH, Baghianimoghdam B. Long arm casting for treatment of trigger finger in children: Report of three cases. *J Med Life.* 2012 Feb 22;5(1):105-6.
16. Lange-Riess D, Schuh R, Hönle W, Schuh A. Long-term results of surgical release of trigger finger and trigger thumb in adults. *Arch Orthop Trauma Surg.* 2009 Dec;129(12):1617-9.
17. Akhtar S, Bradley MJ, Quinton DN, Burke FD. Management and referral for trigger finger/thumb. *BMJ.* 2005 Jul 2;331(7507):30-3.
18. Pataradool K, Buranapuntaruk T. Proximal phalanx injection for trigger finger: Randomized controlled trial. *Hand Surg.* 2011;16(3):313-7.
19. Rozental TD, Zurakowski D, Blazar PE. Trigger finger: Prognostic indicators of recurrence following corticosteroid injection. *J Bone Joint Surg Am.* 2008 Aug;90(8):1665-72.
20. Akhtar S, Burke FD. Study to outline the efficacy and illustrate techniques for steroid injection for trigger finger and thumb. *Postgrad Med J.* 2006 Nov;82(973):763-6.
21. Baumgarten KM, Gerlach D, Boyer MI. Corticosteroid injection in diabetic patients with trigger finger: A prospective, randomized controlled double-blinded study. *J Bone Joint Surg Am.* 2007 Dec;89(12):2604-11.
22. Jongjirasiri Y. The results of percutaneous release of trigger digits by using full handle knife 15 degrees: An anatomical hand surface landmark and clinical study. *J Med Assoc Thai.* 2007 Jul;90(7):1348-55.

23. Uruc V, Cingu A, Emrah Sayit E, Kucukdurmaz F, AYTEKIN MN. Percutaneous trigger finger release with microvitrectomy 19 gauge ophthalmologic knife. *Acta Ortop Bras.* 2011;19(5): 309-11.
24. Gilberts EC, Beekman WH, Stevens HJ, Wereldsma JC. Prospective randomized trial of open versus percutaneous surgery for trigger digits. *J Hand Surg Am.* 2001 May;26(3):497-500.
25. Schramm JM, Nguyen M, Wongworawat MD. The safety of percutaneous trigger finger release. *Hand (N Y).* 2008 Mar;3(1):44-6.
26. Moriya K, Uchiyama T, Kawaji Y. Comparison of the surgical outcomes for trigger finger and trigger thumb: Preliminary results. *Hand Surg.* 2005 Jul;10(1):83-6.
27. de la Parra-Márquez ML, Tamez-Cavazos R, Zertuche-Cedillo L, Martínez-Pérez JJ, Velasco-Rodríguez V, Cisneros-Pérez V. Risk factors associated with trigger finger. Case-control study. *Cir Cir.* 2008 Jul-Aug;76(4):323-7.
28. Sato ES, Gomes Dos Santos JB, Belloti JC, Albertoni WM, Faloppa F. Treatment of trigger finger: Randomized clinical trial comparing the methods of corticosteroid injection, percutaneous release and open surgery. *Rheumatology (Oxford).* 2012 Jan;51:93-9.
29. Paulius KL, Maguina P. Ultrasound-assisted percutaneous trigger finger release: Is it safe? *Hand (N Y).* 2009 Mar;4(1): 35-7.
30. Park MJ, Oh I, Ha KI. A1 Pulley release of locked trigger digit by Percutaneous Technique. *J Hand Surg Br.* 2004 Oct;29(5):502-5.
31. Pegoli L, Cavelli E, Cortese P, Parolo C, Pajardi G. A comparison of endoscopic and open trigger finger release. *Hand Surg.* 2008;13(3):147-51.
32. Zhang C, Tang T, Fu T. Development of a special needle knife for percutaneous A1 pulley release. *J Hand Surg Eur Vol.* 2012 Nov;37(9):889-90.
33. Bain GI, Wallwork NA. Percutaneous A1 pulley release a clinical study. *Hand Surg.* 1999 Jul;4(1):45-50.
34. Calleja H, Tanchuling A, Alagar D, Tapia C, Macalalad A. Anatomic outcome of percutaneous release among patients with trigger finger. *J Hand Surg Am.* 2010 Oct;35(10):1671-4.
35. Zyluk A, Jagielski G. Percutaneous A1 pulley release vs steroid injection for trigger digit: The results of a prospective, randomized trial. *J Hand Surg Eur Vol.* 2011 Jan;36(1):53-6.
36. Habbu R, Putnam MD, Adams JE. Percutaneous release of the A1 pulley: A cadaver study. *J Hand Surg Am.* 2012 Nov;37(11):2273-7.
37. Ha KI, Park MJ, Ha CW. Percutaneous release of trigger digits A technique and results using a specially designed knife. *J Bone Joint Surg Br.* 2001 Jan;83(1):75-7.
38. Blumberg N, Arbel R, Dekel S. Percutaneous release of trigger digits. *J Hand Surg Br.* 2001 Jun;26(3):256-7.
39. Rafee A, Muhammed A, Sulaiman M. Percutaneous release of trigger finger, grade III-IV: A simple outpatient procedure. *J Bone Joint Surg Br.* 2012; 94-B:Suppl 2:S 22.
40. Fu YC, Huang PJ, Tien YC, Lu YM, Fu HH, Lin GT. Revision of incompletely released trigger fingers by percutaneous release: Results and complications. *J Hand Surg Am.* 2006 Oct;31(8):1288-91.
41. Jou MI, Chern TC. Sonographically assisted percutaneous release of the A1 pulley: A new surgical technique for treating trigger digit. *J Hand Surg Br.* 2006 Apr;31(2):191-9.



Correlation of mAgNOR and pAgNOR with Grade of Invasive Ductal Carcinoma of Breast

Khalida Ahtesham, Rozina Jaffer, Ambereen Anwar Imran, Munazza Hasan Sarosh and Majid Salaria

ABSTRACT

Objective: To compare the argyrophilic nucleolar organizer regions (AgNORs) pattern with the histological grade of invasive ductal carcinoma of breast.

Methodology: In this cross sectional study, fifty cases of invasive ductal carcinoma of breast diagnosed on trucut biopsy, core biopsy, incision biopsy or excision biopsy were collected from Lahore General Hospital, Lahore. Hematoxylin & Eosin staining and AgNOR staining were done.

Results: The mean age of the patients was 46.84 years. Maximum number of cases were in 40-49 years age group. The difference in mAgNOR in grade II and grade III tumors was statistically significant whereas the difference in pAgNOR was statistically insignificant.

Conclusion: mAgNOR correlates well with histological grade and results are statistically significant.

Key words: *Argyrophilic Nucleolar Organizer Regions. Breast carcinoma. Modified Bloom and Richardson grade.*

INTRODUCTION

Breast cancer is the most common malignancy in females and a leading cause of death in women throughout the world.¹ Early diagnosis and treatment have improved the disease outcome.² Different studies show that breast cancer is the leading cause of cancer morbidity and mortality in Pakistan.³ Metastasis from carcinoma breast may occur in all grades but those in the Grade III become active sooner, grow more rapidly and produce symptoms causing early mortality. Grading helps in management and treatment. Moreover, Grade I tumors show an excellent response to hormonal treatment as compared to Grade III tumors.⁴

Prognostic indicators of carcinoma of the breast other than histological classification and lymph node metastasis are proliferation activity analysis using oncogene expression, such as c-erbB2, epidermal growth factor receptor, proteolytic enzyme cathepsin and Argyrophilic Nucleolar Organizer Regions (AgNORs).⁵

The nucleolar organiser regions are chromosomal loops of deoxyribonucleic acid (DNA) involved in

ribosomal synthesis. These nucleolar organiser regions are located on each of short arm of the acrocentric chromosomes 13, 14, 15, 21 and 22. Nucleolin and nucleophosmin are the two argyrophilic proteins associated with ribosomal ribonucleic acid (rRNA) transcription and processing.⁶ These proteins are identified by a silver colloid staining technique and visualized as dark intranuclear dots under the microscope.⁷ The dots are fine, round, discrete and singly dispersed in benign tumors whereas they are large, coarse, irregularly distributed and tend to form clusters in malignant tumors.⁸

METHODOLOGY

Fifty samples of invasive ductal carcinoma of breast diagnosed on incisional / excisional biopsy or trucut biopsy were collected in 10% formalin solution from Lahore General Hospital, Lahore. An informed consent was taken from all patients and permission for this study was sought from Hospital Ethical Committee.

The tissues were processed in automatic processor. The sections were taken on slides. Hematoxylin & Eosin (H&E) staining and AgNOR staining were done.^{9,10} Histological diagnosis and grading of the tumor was done on H&E stained slides using Nottingham modification of Bloom and Richardson grading system.⁴

In AgNOR stained sections the nuclei were stained light yellow and AgNORs were visualized as brown black discrete dots of variable sizes within the nuclei. AgNORs were counted in one hundred random nuclei and their mean was calculated to get mAgNOR for each case. The pAgNOR was the percentage of cells with

*Sharif Medical & Dental College, Sharif Medical City,
Sharif Medical City Road, Off Raiwind Road, Jati Umra,
Lahore 54000, Pakistan.*

*Correspondence: Dr. Khalida Ahtesham
Assistant Prof. Department of Pathology
Sharif Medical & Dental College
E-mail: drkhalidahtesham@yahoo.com*

Received: March 16, 2015; Accepted: May 29, 2015.

≥ 5 AgNORs per nucleus.

The data was analyzed using SPSS version 20.0. The quantitative variables were expressed as mean \pm SD. Mean AgNOR count and mean pAgNOR count in grade II and grade III carcinoma of breast was found. The collected data was analyzed by applying Chi-square test. For statistical analysis, p-value of ≤ 0.05 was considered statistically significant.

RESULTS

The ages of the patients ranged from 24-85 years with a mean of 46.84 years. Majority of cases were in 40-49 years age group. In a total of 37 cases of grade II tumors, 12 (32%) had Bloom & Richardson score 6, whereas 25 (68%) had a score of 7. All the 13 (26%) cases of grade III had Bloom and Richardson score 8.

Grade II tumor was dominant in all age groups. Greater proportion of the grade III tumors were found in women less than 45 years age and the difference was statistically significant ($p < 0.02$) (Table 1). The size of the tumor ranged from 2-12cm. Mean tumor size was 3.7 ± 1.8 cm. Grade III tumors had significantly greater ($p < 0.01$) tumor size than grade II tumors (Table 2).

AgNOR count ranged from 2.8-8.6 with mean 3.91 ± 1.02 in grade II tumors and 4.83 ± 1.45 in grade III tumors. Mean AgNOR count was significantly more ($p = 0.02$) in grade III tumors as compared to grade II tumors (Table 3). The AgNOR proliferation index (pAgNOR) ranged from 3 to 86% with mean pAgNOR 22.43 ± 16.4 in grade II tumors and 50.38 ± 22.5 in grade III tumors. However the difference was not statistically significant (Table 4).

Table 1: Grades of tumors in different age groups

Age group (years)	Grade		Total
	II	III	
<45	14	9	23
>45	23	4	27
Total	37	13	50

$P < 0.02$

Table 2: Comparison of tumor sizes with grades of tumors

Size (cm)	Grade		Total
	II	III	
<6	37	9	46
≥ 6	0	4	4
Total	37	13	50

$P < 0.01$

Table 3: Comparison of mean AgNOR counts in different grades of tumor

Grade of tumor	No. of cases	mAgNOR
		Mean \pm SD
II	37	3.91 ± 1.02
III	13	4.83 ± 1.45

$P = 0.02$

Table 4: Comparison of AgNOR proliferation index in different grades of tumor

Grade of tumor	No. of cases	pAgNOR
		Mean \pm SD
II	37	22.43 ± 16.4
III	13	50.38 ± 22.5

p-value = statistically insignificant

DISCUSSION

This study included 50 cases of invasive ductal carcinoma of breast. Invasive ductal carcinoma is the most common form of breast cancer. Carcinoma of no special type have worse prognosis than carcinoma of special type (lobular, medullary, mucinous, papillary, tubular).¹¹ Histological diagnosis and grading was done on H&E stained slides using Nottingham Modification of Bloom and Richardson grading system.⁴ AgNOR staining was done on all the cases and mAgNOR and pAgNOR were determined.

The ages of the patients ranged from 24-85 years with a mean age of 46.84 years. Maximum number of cases were in women greater than 45 years of age (Table 1). This is in accordance with the study conducted at Armed Forces Institute of Pathology (AFIP) Rawalpindi, Pakistan and at Institute of Nuclear Medicine and Oncology, Lahore, Pakistan.¹²

In this study, the size of the tumor ranged from 2-12 cm. Mean tumor size was 3.7 ± 1.8 cm. Grade III tumors had significantly greater ($p < 0.01$) tumor size than grade II tumors. This is in accordance with the study conducted by Mudduwa, on patients with invasive ductal carcinoma of breast that showed mean tumor size of 3.52 ± 2.34 cm.¹³

Microscopic grading was done according to Nottingham modification of Bloom and Richardson grading system.¹ In a total of 37 cases of grade II tumors, 12 (32%) had a Bloom and Richardson score of 6, whereas 25 (68%) had a score of 7. All the cases of grade III tumors had Bloom and Richardson score of 8. Grade II tumor was predominant in all age groups. Greater proportion of the grade III tumors were found in women less than 45 years of age and the difference was statistically significant (Table 1). This is in accordance with the study conducted by Ahmed at The Aga Khan University, Karachi, Pakistan and Khokher at Institute of Nuclear Medicine and Oncology, Lahore, Pakistan.^{3,12}

AgNOR parameters can be used for assessing the aggressiveness of tumor in small incisional biopsy specimen, needle aspiration cytology or imprint cytology.¹⁴

AgNOR dots were counted in 100 nuclei and the mean was determined. In this study, mAgNOR count ranged from 2.8-8.6, with a mean of 3.91 ± 1.02 in grade II tumors, whereas it was 4.83 ± 1.45 in grade III tumors. It was statistically significantly higher ($p = 0.02$) in grade III tumors as compared to grade II tumors (Table 2). In the study conducted by Sharma, mean AgNOR was significantly higher ($p = 0.0137$) in Grade III invasive ductal carcinoma breast (4.28 ± 1.07) than in Grade II tumors.¹⁵ Mean AgNOR also increases in other tissue tumors when the tumor grade is increased. It increased significantly when the histological grade of squamous

cell carcinoma in oral cavity is increased.¹⁶

AgNOR proliferation index is the percentage of nuclei having five or more than five AgNOR granules. The AgNOR proliferation index (pAgNOR) ranged from 3-86% with mean pAgNOR 22.43 ± 16.4 in grade II tumors, and 50.38 ± 22.5 in grade III tumors. The proliferation rate of grade III tumors was higher than grade II tumors. The study conducted by Khan also showed significantly higher pAgNOR ($p < 0.05$) in grade III tumors when compared with grade II tumors of transitional cell carcinoma.¹⁷

This study showed that mAgNOR correlates with histological grade. Therefore, AgNOR staining can be a useful tool to discriminate between low and high grade tumors.

AgNOR staining is done only for research purpose and it is not done in routine laboratory, but it can be used as a proliferation marker to assess the prognosis of cancer patients; as patients with high AgNOR scores are likely to have aggressive tumors. Assessing tumor aggressiveness can also help in making treatment plan and guiding patients for follow up. AgNOR staining can be done in place of or in combination with other proliferation markers like Ki-67 and PCNA as this is a relatively cheaper technique.

CONCLUSION

Different AgNOR parameters correlate well with histological grade. AgNOR staining can discriminate between low and high grade tumors and may be employed to assess tumor aggressiveness and possible response to adjuvant therapy.

REFERENCES

1. Manna AK, Pathak S, Sarkar DK. Role of proliferative markers in breast lesions. *Indian J Surg*. 2010 Feb;72(1):53-7.
2. Kraeima J, Siesling S, Vliegen IM, Klaase JM, IJzerman MJ. Individual risk profiling for breast cancer: Towards tailored follow-up schemes. *Br J Cancer*. 2013 Aug 20;109(4):866-71.
3. Ahmed Z, Khurshid A, Qureshi A, Idrees R, Asghar N, Kayani N. Breast carcinoma grading, estimation of tumor size, axillary lymph node status, staging and Nottingham Prognostic Index scoring on mastectomy specimens. *Indian J Pathol Microbiol* 2009; 52(4): 477-8.
4. Bloom HJG, Richardson WW. Histological grading and prognosis in breast cancer. *Br J Cancer*. 1957 Sep;11(3):359-77.
5. Mourad WA, Devloo S, Setrakian S. Predictors of invasion in ductal carcinoma in situ of the breast: The value of a scoring system. *Ann Saudi Med*. 1997 Jul;17(4):427-31.
6. Derenzini M. The AgNORs. *Micron*. 2000 Apr;31(2):117-20.
7. Bukhari MH, Niazi S, Khan SA, Hashmi I, Perveen S, Qureshi

- SS, Chaudhry NA, Qureshi GR, Hasan M. Modified method of AgNOR staining for tissue and interpretation in histopathology. *Int J Exp Pathol.* 2007 Feb;88(1):47-53.
8. Ansari HA, Mehdi G, Maheshwari V, Siddiqui SA. Evaluation of AgNOR scores in aspiration cytology smears of breast tumors. *J Cytol.* 2008; 25:100-04.
 9. Gamble M, Wilson I. Theory and practice of histological techniques. 5th ed. London: Churchill Livingstone; 2005.
 10. Khalid AW, Khan SA, Chaudhry NA, Tayyab M, Tehseen S. Silver staining nucleolar organizer region (AgNOR) counts in Benign and malignant effusions. *Pak Postgraduate Med J.* 1996; 7: 54-6.
 11. Lester, S.C. Pathologic basis of disease. 9th ed. Philadelphia: Elsevier; 2015.
 12. Khokher S, Mahmood S, Khan SA. Response to neoadjuvant chemotherapy in patients with advanced breast cancer: A local hospital experience. *Asian Pac J Cancer Prev.* 2010;11(2):303-8.
 13. Mudduwa LK. Quick score of hormone receptor status of breast carcinoma: Correlation with the other clinicopathological prognostic parameters. *Indian J Pathol Microbiol.* 2009 Apr-Jun;52(2): 159-63.
 14. Sivridis E, Sims B. Nucleolar organizer regions :New prognostic variable in breast carcinomas. *J Clin Pathol.* 1990 May;43(5):390-2.
 15. Sharma M, Manjari M, Kahlon SK. Proliferative indices, Ki-67 immunostaining and nucleolar organizer region associated protein and their association with various grades of breast carcinomas. *J Clin Diag Res.* 2011;5(7): 1371-4.
 16. Gulia SP, Sitaramam E, Reddy KP. The role of silver staining nucleolar organizer regions (AgNORs) in lesions of the oral cavity. *J Clin Diag Res.* 2011; 5(5):1011-5.
 17. Khan AH, Khan SA, Chaudhry NA, Tayyab M. Comparison of argyrophilic nucleolar organizer regions (AgNORS) with proliferating cell nuclear antigen (PCNA) in different grades of transitional cell carcinoma of urinary bladder. *Annals of King Edward Medical University* 2007; 13: 186-90.



Clinical Spectrum, Grades of Severity and Outcome of Children With Dengue Fever

Syed Qamar Zaman, Emran Roshan and Arshad Mahmood

ABSTRACT

Objective: To study the clinical spectrum, grades of severity and outcome of children with dengue fever.

Methodology: It was a descriptive study conducted at paediatric department of PNS Shifa Hospital, Karachi from January 2007 to December 2012. Study population included 50 children of either gender aged 5 months to 13 years having dengue infection admitted in paediatric ward at PNS Shifa Naval Hospital Karachi. All children with dengue IgM antibodies positive by ELISA were included in the study. Dengue fever was classified according to WHO classification of dengue infections and they were managed according to the grades of severity.

Results: A total of 50 patients with positive dengue serology were studied. Mean age of children was 7.4 years with interquartile range of 4.6 and majority were male (56%). Common clinical findings were fever (100%), tachycardia (70%), vomiting (48%), skin rashes (32%), headache (28%), abdominal pain (24%), hepatomegaly (24%), significant bleeding manifestations (20%), myalgia/arthralgia (18%), splenomegaly (16%) and jaundice (8%). Common laboratory findings were thrombocytopenia (42%), anemia (34%), leukopenia (26%), deranged prothrombin time/partial thromboplastin time (44%), increased packed cell volume (18%) and deranged ALT (8%). Statistically significant correlation was seen between age and gender (p value=0.001), age and bleeding (p value=0.010), fever and tachycardia (p value=0.006), general appearance and hospital stay (p value=0.001), bleeding and platelet transfusion (p value=0.004), hepatomegaly and fresh frozen plasma transfusion (p value=0.007) using Pearson Chi-square method.

Conclusion: Fever, hemorrhagic manifestations, vomiting, headache, abdominal pain, hepatomegaly, thrombocytopenia and evidence of plasma leakage (hemoconcentration) should lead a clinician to suspect dengue infection.

Keywords: Dengue. Bleeding manifestations. Skin rashes. Thrombocytopenia. Leucopenia.

INTRODUCTION

Dengue fever is a rapidly emerging mosquito-borne Arboviral infection. Initial reports of dengue fever have been sporadic but recently, epidemics of dengue fever have become a regular occurrence. In one report, it was stated that up to 100 million individuals are infected with dengue fever worldwide per annum and up to 500,000 people end up being admitted in a hospital.¹ Estimates showed that approximately 3.5 billion people live in countries at a risk for dengue.² The global incidence of dengue fever has increased over the last 60 years with a transition from epidemic type dengue with long inter-epidemic intervals to endemic type with seasonal fluctuation.³⁻⁵

The presence of dengue virus has been detected in local populations in Pakistan since 1960s. Since 2006 in Pakistan, dengue outbreaks have happened regularly on annual basis with disease spreading to most major cities. Dengue now affects thousands of

people and has caused hundreds of deaths. Dengue infection is now a recognised major health hazard in Pakistan and it is likely to increase in the coming years.⁶ Out breaks of dengue haemorrhagic fever have been reported in the Khyber Pakhtunkhwa (KPK) and Federal Administered Tribal Areas (FATA) of Pakistan which has witnessed a huge influx of migrants due to violent conflicts in Afghanistan and is augmented by an already impoverished society and its own wide diversity of potential arthropod vectors.⁷ Infection with any of dengue serotypes can range from clinically asymptomatic state to the more severe forms of infection of which dengue shock syndrome (DSS) is the most serious one and results in maximum mortality.^{8,9} Dengue infections are 12.1% of febrile illnesses attending the hospitals including undifferentiated fever (UF) (49.8%), dengue fever (DF) (39.3%) and dengue haemorrhagic fever (DHF) (10.9%).¹⁰ Classic dengue fever (DF) presents with high grade fever, retrobulbar discomfort, severe myalgias and skin rash. However, in more severe forms of infection, the disease may progress to potentially fatal dengue haemorrhagic fever or dengue shock syndrome (DHF/DSS). This syndrome leads to vascular incompetency and fluid extravasation that may cause hypovolemic shock.¹¹ Children with DHF are known to suffer from higher case fatality ratio than adults.¹²

PNS Shifa Hospital,
Karachi 75500, Pakistan

Correspondence: Dr. Syed Qamar Zaman
Senior Registrar Department of Paediatrics
PNS Shifa Hospital
E-mail: sqzaman@gmail.com

Received: March 16, 2015; Accepted: June 6, 2015.

Prompt recognition of patients at risk of developing severe dengue infection is vital in providing timely critical care and this lead to reduced risk of case fatality (<1%). Dengue fever can mimic other febrile illnesses (OFIs) early in course of disease, since symptoms may be non-specific and may be present in OFIs such as malaria and typhoid fever in dengue endemic areas.¹³

Recent studies have shown that petechiae, thrombocytopenia (platelet count <100,000 cells/mm³) and positive tourniquet test can differentiate between dengue fever and OFIs.¹⁴⁻¹⁶

Treated DHF/DSS is associated with 3% mortality whereas untreated is associated with 20% mortality.¹⁷ Dengue infection can be readily and cost efficiently diagnosed though dengue IgM antibodies compared with other classical serological methods like hemagglutination and complement fixation tests.¹⁸

The present study was done to analyze the trend of DF over the years along with the clinical features, complications and outcome of cases admitted at the PNS Shifa Naval Hospital Karachi.

METHODOLOGY

This descriptive study was carried out at Paediatric Department of PNS Shifa Naval Hospital Karachi from January 2007 to December 2012. The study population consisted of children of Army/Navy personnel and civilians reporting to PNS Shifa Naval Hospital for medical treatment or those referred from primary or secondary care hospitals for evaluation of atypical febrile illness. All children of either gender from 5 months to 13 years of age with positive dengue IgM by ELISA or immunochromatography were included in the study. Children with negative dengue serology were excluded from the study.

All patients meeting the inclusion criteria were evaluated after informed consent of the parents. Data was collected on a predesigned proforma for each

child. This included demographic data, symptoms, signs and laboratory investigations for blood counts, platelet count, coagulation profile and liver function tests. Every child was examined thoroughly from head to toe for signs of shock, rash, hemorrhagic manifestations and any systemic involvement. Blood pressure (BP) was recorded and tourniquet test was performed to check capillary fragility (test was positive if more than 20 petechiae were present in an area of one inch below the BP cuff). Children under study were categorized into DF, DHF or DSS according to World Health Organization (WHO) clinical case definitions and grading of severity of their illness was done on basis of WHO criteria for severity of dengue infection. All children with leucopenia or thrombocytopenia were followed till their blood counts were within normal range. The study was approved by the PNS Shifa Hospital Research and Ethical Committee.

Sample size was calculated using World Health Organization (WHO) calculator. All data was analyzed using Statistical Package for Social Sciences (SPSS) version 15.0. Descriptive statistics like frequencies and percentages of various variables were calculated where required. Associations between all variables were calculated using Pearson Chi-Square method. With confidence level of 95%, p-value of less than 0.05 was considered significant.

RESULTS

A total of 50 patients fulfilling the inclusion criteria were evaluated and it was observed that 3 (6%) were 5 months to 1 year old; 9 (18%) were 1 to 5 years old and 38 (76%) were 5 to 13 years old. Mean age was 7.4 years with interquartile rangem of 4.6 (range 5 months to 13 years). Males were 28 (56%) and 22 (44%) were females with a male to female ratio of 1.2:1.

Common clinical findings are depicted in Table 1a.

Table 1a: Common clinical findings

Sr. No	Signs / Symptoms	Percentage (%)
1	Fever	100
2	Tachycardia	70
3	Vomitting	48
4	Rash	32
5	Headache	28
6	Abdominal Pain	24
7	Hepatomegaly	24
8	Bleeding Manifestations	20
9	Myalgia / Arthralgia	18
10	Splenomegaly	16
11	Jaundice	8
12	Ascites / Plueral Effusion	4

Table 1b: Common laboratory findings

Sr. No	Signs / Symptoms	Percentage (%)
1	Anaemia	34
2	Leucopenia	26
3	Thrombocytopenia	42
4	Increased Hematocrit	18
5	Deranged PT/APTT	44
6	Raised ALT	8
7	IgM - Dengue	100
8	IgG - Dengue	8

WHO criteria for grading severity in dengue infections was used and it was observed that majority (59%) of children had DF. Children with DSS/DHF required supportive therapy with blood products i.e. platelet transfusion (34%), fresh frozen plasma (26%), red cell concentrate (20%). Majority of children remained hospitalized for one week (58%) and 2 (4%) children expired

Statistically significant correlation was seen between age and gender (p value=0.001), age and bleeding (p value=0.010), fever and tachycardia (p value=0.006), general appearance and hospital stay (p value=0.001), bleeding and platelet transfusion (p value=0.004), packed cell volume and fresh frozen plasma transfusion (p value=0.015), hepatomegaly and fresh frozen plasma transfusion (p value=0.007) using Pearson Chi-square method. There was no correlation between platelet count and bleeding manifestation and bleeding and hospital stay (p value=0.148).

DISCUSSION

Dengue fever is one of the major re-emerging systemic infections with a steady increase in its geographic spread, number of cases and severity of the disease in the past four to six decades. This may be due to increasing urbanization and availability of transport facilities in various rural areas of Pakistan. The epidemics of dengue have been commonly associated with the rainy season. The peak incidence of dengue fever was reported from August to October in Pakistan.¹⁹ However, the peak incidence of dengue infections was from October to December in this study. This timing is explained by delayed onset of monsoon rains in 2007. This pattern is similar to dengue epidemic in Chandigarh, India.²⁰ Majority of children were from peri-urban slums that can host breeding of mosquitos due to inadequate solid and water waste management, practices of water storage for domestic usage and overcrowded living conditions.²¹ One sixth of the cases were from villages indicating the extension of the epidemic in rural areas.²² Majority (76%) of the cases in this study were 5-13 years of age. Male preponderance was observed in present study as it was

in other studies from Pakistan and India.^{20,23} This could be due to the fact that in these social groups, males spend more time outdoors and are thus more exposed to risk of mosquito bites. As regards the clinical presentation, fever has been the commonest finding in all epidemics including the present study.²¹⁻²⁴ Mean duration of fever was 6 days with 84% children having high grade intermittent pattern in the current study.

Vomiting, headache, abdominal pain, bleeding, myalgia and arthralgia were other common clinical manifestations in present study. These were also common presenting features in other epidemics in Karachi.¹⁹ However, a recently concluded review was unable to make any conclusions on the signs and symptoms that can differentiate between dengue and OFIs.²⁵ In the present study, skin rashes were found in 32% children of which 18% had petechiae and bruises, 10% had maculopapular rash over the face and extremities and 4% had confluent red macular rashes involving both legs. Spontaneous hemorrhage occurred in 10(20%) children in the form of gastrointestinal hemorrhage and epistaxis in present study. The reported frequency of rash in dengue fever ranges from 50-66%.²⁶ Rash, melena, and epistaxis were the common hemorrhagic manifestations seen.²⁷

Hepatomegaly was found in 24% of children however, only 8% had jaundice and splenomegaly was present in 16% of patients in the present study. This was also observed in other Pakistani children and other South East Asian studies.²⁸ Common laboratory findings in present study were thrombocytopenia (42%), anaemia in 34%, leukopenia (26%), deranged prothrombin time/partial thromboplastin time (PT/PTT) (44%), increased packed cell volume (18%) and raised ALT (8%). Luiz has suggested the use of markers such as ALT and AST as parameters to evaluate severity in patients with dengue fever.²⁹ Since grossly elevated liver enzymes are known to be an early warning sign for severe disease and clinical bleeding, vigorous follow up in such patients is warranted. Early identification of patients with dengue at risk of developing hemorrhage is an important clinical objective. It was observed that leukopenia was significantly more common in patients

with DF. On the other hand, raised neutrophil and monocyte counts were more common in patients with DHF.³⁰

Prolonged fever for more than 7 days, flushed appearance, pharyngeal congestion, serous effusion, bleeding manifestations, thrombocytopenia, elevated liver enzymes and elevated PCV were associated with development of dengue haemorrhagic fever and dengue shock syndrome.²³ The present study also showed that shock, bleeding, thrombocytopenia, deranged PT/PTT and elevated ALT were predictors of severity of dengue. In our study, DF was more common (59%) than DHF. In a study in Thailand, dengue infections were 12.1% of febrile illnesses attending the hospital including UF (49.8%), DF (39.3%) and DHF (10.9%).¹⁰ In present study, 2 (4%) children developed dengue shock syndrome and expired despite resuscitation measures due to circulatory collapse. Mortality in another study in India was 3.5%.²⁴

CONCLUSION

Dengue virus is now endemic in the country, circulating throughout the year with a peak incidence in the postmonsoon period. Median age of dengue patients has decreased and younger patients may have become more susceptible. Fever, hemorrhagic manifestations, hepatomegaly, thrombocytopenia, and evidence of plasma leakage (hemoconcentration, pleural effusion, ascites or hypoproteinemia) should lead a clinician to suspect severe dengue infection.

RECOMMENDATIONS

Due to the limitations of this study, it is recommended for future investigations to increase sample size, extend period of investigation, to include patients admitted in other hospitals in locality and conduct investigation in all age groups.

REFERENCES

- Bharaj P, Chahar HS, Pandey A, Diddi K, Dar L, Guleria R, Kabra SK, Broor S. Concurrent infections by all four dengue virus serotypes during an outbreak of dengue in 2006 in Delhi, India. *Virol J*. 2008 Jan 9;5:1.
- Beatty M, Letson W, Edgil D, Margolis H. Estimating the total world population at risk for locally acquired dengue infection. *Am J Trop Med Hyg*. 2007;77 Suppl 5:S170-257.
- Gibbons RV, Vaughn DW. Dengue: An escalating problem. *BMJ*. 2002 Jun 29;324(7353):1563-6.
- Guzman MG, Kouri G. Dengue: An update. *Lancet Infect Dis*. 2002 Jan;2(1):33-42.
- Thai KT, Cazelles B, Nguyen NV, Vo LT, Boni MF, Farrar J, Simmons CP, van Doorn HR, de Vries PJ. Dengue dynamics in Binh Thuan province, southern Vietnam: Periodicity, synchronicity and climate variability. *PLoS Negl Trop Dis*. 2010 Jul 13;4(7):e747.
- Rasheed SB, Butlin RK, Boots M. A review of dengue as an emerging disease in Pakistan. *Public Health*. 2013 Jan;127(1):11-7.
- Nieto NC, Khan K, Ullah G, Teglas MB. The emergence and maintenance of vector-borne diseases in the Khyber Pakhtunkhwa province and the Federally Administered Tribal Areas of Pakistan. *Front Physiol*. 2012; 3:250-7.
- Harrington LC, Edman JD, Scott TW. Why do female *Aedes aegypti* (Diptera: Culicidae) feed preferentially and frequently on human blood? *J Med Entomol*. 2001 May;38(3):411-22.
- Horstick O, Farrar J, Lum L, Martinez E, San Martin JL, Ehrenberg J, Velayudhan R, Kroeger A. Reviewing the development, evidence base and application of the revised dengue case classification. *Pathog Glob Health*. 2012 May;106(2):94-101.
- Sirivichayakul C, Limkittikul K, Chanthavanich P, Jiwariyavej V, Chocejindachai W, Pengsaa K, Suvannadabba S, Dulyachai W, Letson GW, Sabchareon A. Dengue infection in children in Ratchaburi, Thailand. Clinical manifestations. *PLoS Negl Trop Dis*. 2012;6(2):e1520.
- Guzman MG, Halstead SB, Artsob H, Buchy P, Farrar J, Gubler DJ, Hunsperger E, Kroeger A, Margolis HS, Martinez E, Nathan MB, Pelegrino JL, Simmons C, Yoksan S, Peeling RW. Dengue: A continuing global threat. *Nat Rev Microbiol*. 2010 Dec;8 Suppl 12:S7-161.
- Hammond SN, Balmaseda A, Pérez L, Tellez Y, Saborío SI, Mercado JC, Videá E, Rodríguez Y, Pérez MA, Cuadra R, Solano S, Rocha J, Idiaquez W, Gonzalez A, Harris E. Differences in dengue severity in infants, children and adults in a 3-year hospital-based study in Nicaragua. *Am J Trop Med Hyg*. 2005 Dec;73(6):1063-70.
- Watt G, Jongsakul K, Chouriyagune C, Paris R. Differentiating dengue virus infection from scrub typhus in Thai adults with fever. *Am J Trop Med Hyg*. 2003 May;68(5):536-8.
- Potts JA, Thomas SJ, Srikiatkachorn A, Supradish PO, Li W, Nisalak A, Nimmannitya S, Endy TP, Libraty DH, Gibbons RV, Green S, Rothman AL, Kalayanaroj S. Classification of dengue illness based on readily available laboratory data. *Am J Trop Med Hyg*. 2010 Oct;83(4):781-8.
- Low JG, Ong A, Tan LK, Chaterji S, Chow A, Lim WY, Lee KW, Chua R, Chua CR, Tan SW, Cheung YB, Hibberd ML, Vasudevan SG, Ng LC, Leo YS, Ooi EE. The early clinical features of dengue in adults: Challenges for early clinical diagnosis. *PLoS Negl Trop Dis*. 2011;5(5):e1191.
- Gregory CJ, Santiago LM, Arguello DF, Hunsperger E, Tomashek KM. Clinical and laboratory features that differentiate dengue from other febrile illnesses in an endemic area—Puerto Rico, 2007-2008. *Am J Trop Med Hyg*. 2010 May;82(5):922-9.
- Vijayakumar TS, Chandy S, Sathish N, Abraham M, Abraham P, Sridharan G. Is dengue emerging as a major public health

- problem? *Indian J Med Res.* 2005 Feb;121(2):100-7.
18. Keating J. An investigation into the cyclical incidence of dengue fever. *Soc Sci Med.* 2001 Dec;53(12):1587-97.
 19. Khan E, Siddiqui J, Shakoor S, Mehraj V, Jamil B, Hasan R. Dengue outbreak in Karachi, Pakistan, 2006: Experience at a tertiary care center. *Trans R Soc Trop Med Hyg.* 2007 Nov;101(11):1114-9.
 20. Ratho RK, Mishra B, Kaur J, Kakkar N, Sharma K. An outbreak of dengue fever in periurban slums of Chandigarh, India, with special reference to entomological and climatic factors. *Indian J Med Sci.* 2005 Dec;59(12):518-26.
 21. Guzman MG, Kourf G. Dengue in Cuba: Research strategy to support dengue control. *Lancet.* 2009 Nov 14;374(9702):1660-1.
 22. Ghosh SK, De S, Sarkar U, Ghosh M, Chatterjee MK, Samanta S. Clinical profile of dengue during 2005 outbreak in Kolkata and predictive markers of dengue haemorrhagic fever. *J Indian Med Assoc.* 2011 Nov;109(11):790-3.
 23. Qureshi JA, Notta NJ, Salahuddin N, Zaman V, Khan JA. An epidemic of Dengue fever in Karachi-Associated clinical manifestations. *J Pak Med Assoc.* 1997 Jul;47(7):178-81.
 24. Joshi R, Bald V. Profile of dengue patients admitted to a tertiary care hospital in Mumbai. *Turk J Pediatr.* 2011 Nov-Dec;53(6):626-31.
 25. Potts JA, Rothman AL. Clinical and laboratory features that distinguish dengue from other febrile illnesses in endemic populations. *Trop Med Int Health.* 2008 Nov;13(11):1328-40.
 26. Ying RS, Tang XP, Zhang FC, Cai WP, Chen YQ, Wang J, Hong WX, Long YZ. Clinical characteristics of the patients with dengue fever seen from 2002 to 2006 in Guangzhou. *Zhonghua Shi Yan He Lin Chuang Bing Du Xue Za Zhi.* 2007 Jun;21(2):123-5.
 27. Kumar A, Rao CR, Pandit V, Shetty S, Bammigatti C, Samarasinghe CM. Clinical manifestations and trend of dengue cases admitted in a tertiary care hospital, Udipi district, Karnataka. *Indian J Community Med.* 2010 Jul;35(3):386-90.
 28. Akram DS, Igarashi A, Takasu T. Dengue virus infection among children with undifferentiated fever in Karachi. *Indian J Pediatr.* 1998 Sep-Oct;65(5):735-40.
 29. de Souza LJ, Nogueira RM, Soares LC, Soares CE, Ribas BF, Alves FP, Vieira FR, Pessanha FE. The impact of dengue on liver function as evaluated by aminotransferase levels. *Braz J Infect Dis.* 2007 Aug;11(4):407-10.
 30. Murgue B, Deparis X, Chungue E, Cassar O, Roche C. Dengue: An evaluation of dengue severity in French Polynesia based on an analysis of 403 laboratory-confirmed cases. *Trop Med Int Health.* 1999 Nov;4(11):765-73.



Single Incision Laparoscopic Appendectomy (SILA) by Conventional Laparoscopic Instruments; An Initial Single Surgeon Experience of 30 Cases of Uncomplicated Acute Appendicitis at Sharif Medical City Hospital, Lahore

Muhammad Saad Faisal, Sidra Dil Muhammad, Ahsen Nazir Ahmed, Muhammad Adnan Khan, Zille Maryum and Kausar Abbas

ABSTRACT:

Objective: To describe our initial experience of simplified and low cost SILA technique carried out with conventional laparoscopic instruments. **Methodology:** This prospective study was conducted from December 2014 to May 2015 at Sharif Medical City Hospital, Lahore. We accomplished SILA among 30 cases for uncomplicated acute appendicitis using conventional non reticulating laparoscopic instruments, 0° telescope, two 10 mm ports and a directly introduced non reticulating curved grasper through the same skin incision without the use of any port that served to hold the appendix. The appendicular artery was secured with liga clips without use of ultrasonic shear. The ligation of appendix was performed by Vicryl no. 1/0. No special technique was used to retrieve appendix specimen.

Results: SILA were completed in all patients successfully without the need of additional port in the same or through separate skin incision or conversion to an open approach. The mean operative time was 22.65 ± 1.04 minutes. All patients were discharged within two days. No significant intraoperative or postoperative complications were noted over a period of two months follow up. Wound healed in all patients with an invisible scar.

Conclusion: The single incision laparoscopic appendectomy technique by using conventional non reticulating laparoscopic instruments in this study is cost effective. It is safe for treatment of patients with uncomplicated acute appendicitis. Thus, it can be performed in a hospital equipped with basic laparoscopic surgical instruments.

Key word: Single incision laparoscopic appendectomy. 0° telescope. Conventional.

INTRODUCTION

Acute appendicitis is the most common disease requiring emergency surgery in the surgical field and appendectomies being one of the most basic surgeries for the surgeons.¹

The open appendectomy was performed first by McBurney in 1894 and since then, it is the gold standard treatment for acute appendicitis.² With the introduction of laparoscopy by Semm in 1983, the laparoscopic appendectomy has been conducted more frequently than the open appendectomy due to its advantages of being minimally invasive and having a shorter length of stay accompanied by a faster return of bowel function, decreased use of narcotics and lower rates of wound complications.³⁻⁵ During the era of laparoscopic surgery, common trend has been towards less invasive techniques and a natural extension of the trend is to perform operations without scars.^{6,7} Today, the two most prominent techniques for

scarless surgery are transumbilical single-incision laparoscopic surgery (SILS) and natural orifice transluminal endoscopic surgery (NOTES). However, NOTES is not very popular due to its technical and logistic difficulties. SILS seems to be ready for wider use in surgical community.^{8,9} The first report of single-incision laparoscopic surgery was in 1992 by Pelosi who performed a laparoscopic appendectomy, and in 1997 by Navarra who performed a SILS cholecystectomy.^{10,11}

Here we mention the initial experience of simple and low cost technique of SILA among patients with uncomplicated acute appendicitis, with the use of conventional laparoscopic instruments. This technique can be converted at any time to conventional multi incision, multi ports laparoscopic appendectomy or open approach, if required.

METHODOLOGY

Thirty patients with uncomplicated acute appendicitis underwent SILA by a single surgeon (having at least 5 years experience of performing laparoscopic surgeries) from December 2014 to May 2015 at Sharif Medical City Hospital, Lahore.

Sharif Medical & Dental College, Sharif Medical City,
Sharif Medical City Road, Off Raiwind Road, Jati Umra,
Lahore 54000, Pakistan.

Correspondence: Dr. Muhammad Saad Faisal
Assistant Prof. Department of Surgery
Sharif Medical & Dental College
E-mail: saadi206@gmail.com

Received: March 16, 2015; Accepted: May 21, 2015.

All patients were fully informed about the SILA surgery and other possible therapeutic options, including traditional multi incision laparoscopic and open appendectomy. Written informed consent was provided by all patients. The study was approved by Hospital Ethical Committee.

The operation was performed through single transumbilical skin incision using conventional laparoscopic instruments, 0° laparoscope, non reticulating laparoscopic instruments and ordinary electro cautery with help of two 10mm ports and directly introduced curved grasper, that helped to suspend appendix during procedure.

All outcomes including blood loss, operative time, complications, length of stay and pain were recorded along with patients' data. Data was analyzed using SPSS version 20.0.

Patients of all age groups and both gender with uncomplicated acute appendicitis diagnosed on clinical evidence provided by history, physical examination, abdominal ultrasonography and abdominal computed tomography scan were included in the study.

Patients with evidence of appendicular mass, perforated or gangrenous base of appendix, abscess formation, diffuse peritonitis, dense adhesion, abnormal position of appendix and any other pathology on clinical and radiological exam and those with contraindication for general anaesthesia and pneumoperitoneum were excluded from the study.

Surgical Technique

All patients received intravenous 1st generation cephalosporin at induction of anaesthesia. After surgery, patients were administered two or more doses of antibiotics. Preoperative preparation and anaesthesia were performed in the standard manner. When performing SILA, the umbilicus was cleaned thoroughly using standard 10% iodine soaked cotton swabs. Manual evacuation of debris was done routinely.

In SILA, a 1.5-2.0 cm longitudinal skin incision was made through the everted umbilicus and we used a Verres needle followed by a closed access method for establishing the pneumoperitoneum, that was initiated to a pressure of 12 mm Hg. Two ports of 10mm were

introduced through linea alba in the midline, above and below umbilicus. Both ports were placed through the same skin incision but at different fascial incisions. The patient was then put in a Trendelenburg position and rotated to the left to secure easy access to appendix.

A 10mm 0° optic fibre was used in all operations that was inserted through one port. We visualized the location of the appendix by using two straight instruments, one through the second 10mm port that explored the right lower abdominal quadrant and other instrument (curved non reticulating grasper) was embedded directly through same skin incision but a separate facial defect to suspend appendix (Figure 1).

In all patients, mesoappendix was dealt with electrocautery and laparoscopic scissors after securing appendicular artery with liga clips LT 300 on a standard 10mm clip applicator. Subsequently, the exposed base of appendix was ligated using extracorporeal roaders knot with absorbable suture (Vicryl 1/0) (Figure 2). The resected appendix was taken out through 10mm port. There was no need of any bag to remove the resected appendix, since the wound retractor protected the entire circumference of the incision from contamination in case of any difficulty in extraction of specimen and the need for extension of facial incision.

Hemostasis and complications such as intestinal perforation in the abdominal cavity had been confirmed at the end of the procedure. No drainage was required in any of the patients. Ports and grasper were removed under vision and abdomen was deflated. Fascia was closed carefully with interrupted non absorbable suture (Prolene 2/0) and the skin was also closed in the same manner. After adequate closure, the immediate cosmetic effect was excellent (Figure 3). A gauze ball was placed on the depression of the umbilicus.

All patients were allowed a clear fluid diet after full recovery from general anaesthesia and semisolid diet was allowed as tolerated. All patients recovered well and were discharged in good condition without any complications.

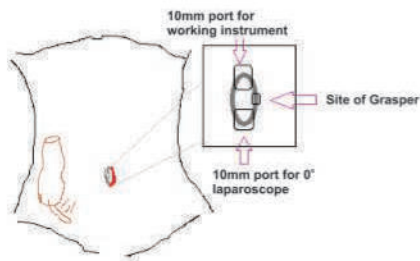


Figure 1: Location of both 10mm ports and directly introduced grasper through umbilicus

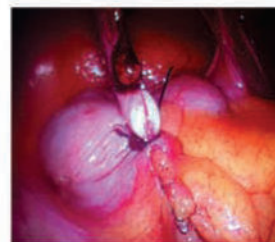

Figure 2: Clip and knot over the mesoappendix and base of appendix

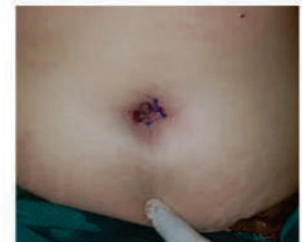

Figure 3: Closed wound of SILA

RESULTS

The mean age of patients in this study was 26.25±5.04 years. 11 (36.67%) patients were male and 19 (63.33%) were female. 15 (50%) out of 30 had normal body mass index (BMI), 12(40%) were overweight and 3(10%) were obese. 8 patients were with comorbid conditions, 4 with controlled diabetes mellitus (M:F, 3:1), 4 with controlled hypertension (all females). Only one male patient was cigarette smoker. 9 females had past history of caesarian section.

In spite of technical difficulties and disorientation especially in the first few cases, the mean operative time was 22.65±1.04minutes. There were no conversions to multi incision conventional laparoscopy or open appendectomy. The mean postoperative stay was 1.01±2.01 days.

Following are the mean operative time (Table 1) and complications of procedure (Table 2).

DISCUSSION

Laparoscopic appendectomy is widely performed for the treatment of acute appendicitis. Single port laparoscopic appendectomy is rapidly gaining admiration due to improved cosmesis and reduced parietal trauma.¹²⁻¹⁴

Several single port systems have been used to introduce laparoscopic instruments into the abdominal cavity. Some authors have reported the use of pre-manufactured one port systems.¹⁵⁻¹⁸ Others have reported on the glove port method.^{19,20} In this study, two 10mm traditional laparoscopic ports for SILA were utilized and direct non stop use of non reticulating grasper all through umbilicus.

Performing SILA requires experience in laparoscopic

surgery and a certain number of cases must be performed to overcome the learning curve. In this study, the mean operation time was 22.65±1.04 minutes. The cases in the beginning phase took longer than average. As the cases accumulated, operator experience was gained, the operation time started to shorten.

No patient required drainage and conversion to multi incision laparoscopic or open appendectomy; keeping the SILA meaningful for uncomplicated acute appendicitis.

The lower incidence of surgical site infection is one of the primary advantages of laparoscopic appendectomy over conventional surgery. In the report of Oltmann, they reported the incidence of wound complication up to 1(5.2%) and Visnjic reported as 4 (13.7%).^{21,22} The higher incidence of port site infection could be expected in single incision laparoscopic surgery for appendectomy than conventional 3-port laparoscopic appendectomy, especially in extracorporeal appendectomy due to the exposure and manipulation of the appendix on the incision site. Therefore, an adjusted operative technique using minimal, gentle movements and adequate wound protection is required. We routinely used 10mm port for extraction of specimen or a wound retractor/ gauze for wound protection in case of direct retrieval of large sized specimen through the wound after extending the facial incision. Neither wound seroma nor wound infection developed in any of the cases. To minimize the operative bias, all the surgeries were performed by a single surgeon.

There are certain limitations. This is a single center study, with a limited sample size. A series of studies on larger patient groups should be conducted if SILA with conventional laparoscopic instruments is to be established as the preferred feasible and low cost

Table 1: Mean operative time of the procedure

No. of cases	Mean operative time (min.)
First 10 cases	51.15±6.43
Next 10-20 cases	39.12±2.09
Last 10 cases	18.94±9.04

Table 2: Complications of the procedure

Parameters	No. of patients	Percentage (%)	
Intraoperative complications	Intraoperative Hemorrhage	0	
	Iatrogenic Gut injury	0	
Postoperative complications	Port site complications	Seroma	0
		Hematoma	1
		Infection	0
	Pelvic abscess	0	
	Urinary retention	0	
	Paralytic ileus	0	
Re – exploration	0		
Mortality (within hospital stay)	0		

scarless surgery for uncomplicated acute appendicitis patients.

CONCLUSION

SILA technique with conventional laparoscopic instruments is feasible, safe and low cost for uncomplicated acute appendicitis and for explorative laparoscopy as well.

REFERENCES

- Masoomi H, Nguyen NT, Dolich MO, Wikholm L, Naderi N, Mills S, Stamos MJ. Comparison of laparoscopic versus open appendectomy for acute non-perforated and perforated appendicitis in the obese population. *Am J Surg.* 2011 Dec;202(6):733-8.
- McBurney C. The incision made in the abdominal wall in cases of appendicitis, with a description of a new method of operating. *Ann Surg.* 1894 Jul;20(1):38-43.
- Semm K. Endoscopic appendectomy. *Endoscopy.* 1983 Mar;15(2):59-64
- Rispoli G, Armellino MF, Esposito C. One-trocar appendectomy. *Surg Endosc.* 2002 May;16(5):833-5.
- D'ambra L, Berti S, Bonfante P, Bianchi C, Magistrelli P, Bianco A, Gianquinto D, Feleppa C, Deidda E, Falco E. Laparoscopic appendectomy for complicated acute appendicitis. *G Chir.* 2011 Apr;32(4):181-4.
- Rehman H, Rao AM, Ahmed I. Single incision versus conventional multi-incision appendectomy for suspected appendicitis. *Cochrane Database Syst Rev.* 2011 Jul 6;(7):CD009022.
- Chouillard E, Dache A, Torcivia A, Helmy N, Ruseykin I, Gumbs A. Single-incision laparoscopic appendectomy for acute appendicitis: A preliminary experience. *Surg Endosc.* 2010 Aug;24(8):1861-5.
- Hansen EN, Muensterer OJ, Georgeson KE, Harmon CM. Single incision pediatric endosurgery: Lessons learned from our first 224 laparoendoscopic single-site procedures in children. *Pediatr Surg Int.* 2011 Jun;27(6):643-8.
- Garey CL, Laituri CA, Ostlie DJ, St Peter SD. A review of single site minimally invasive surgery in infants and children. *Pediatr Surg Int.* 2010 May;26(5):451-6.
- Pelosi MA, Pelosi MA 3rd. Laparoscopic appendectomy using a single umbilical puncture (minilaparoscopy). *J Reprod Med.* 1992 Jul;37(7):588-94.
- Navarra G, Pozza E, Occhionorelli S, Carcoforo P, Donini I. One-wound laparoscopic cholecystectomy. *Br J Surg.* 1997 May;84(5):695.
- Hong TH, Kim HL, Lee YS, Kim JJ, Lee KH, You YK, Oh SJ, Park SM. Trans umbilical single-port laparoscopic appendectomy (TUSPLA): Scarless intracorporeal appendectomy. *J Laparoendosc Adv Surg Tech A.* 2009 Feb;19(1):75-8.
- Vidal O, Valentini M, Ginestà C, Martí J, Espert JJ, Benarroch G, García-Valdecasas JC. Laparoendoscopic single-site surgery appendectomy. *Surg Endosc.* 2010 Mar;24(3):686-91.
- Saber AA, Elgamel MH, El-Ghazaly TH, Dewoolkar AV, Akl A. Simple technique for single incision trans umbilical laparoscopic appendectomy. *Int J Surg.* 2010;8(2):128-30.
- Ito M, Asano Y, Horiguchi A, Shimizu T, Yamamoto T, Uyama I, Miyakawa S. Cholecystectomy using single-incision laparoscopic surgery with a new SILS port. *J Hepatobiliary Pancreat Sci.* 2010 Sep;17(5):688-91.
- Song T, Kim TJ, Kang HJ, Choi CH, Lee JW, Bae DS, Kim BG. Single-port access laparoscopic surgery using a novel laparoscopic port (Octo-Port). *Taiwan J Obstet Gynecol.* 2011 Dec;50(4):436-40.
- Saber AA, El-Ghazaly TH. Early experience with single incision transumbilical laparoscopic adjustable gastric banding using the SILS Port. *Int J Surg.* 2009 Oct;7(5):456-9.
- Saber AA, El-Ghazaly TH. Single-incision transumbilical laparoscopic right hemicolectomy using SILS Port. *Am Surg.* 2011 Feb;77(2):252-3.
- Lee YS, Kim JH, Moon EJ, Kim JJ, Lee KH, Oh SJ, Park SM, Hong TH. Comparative study on surgical outcomes and operative costs of transumbilical single-port laparoscopic appendectomy versus conventional laparoscopic appendectomy in adult patients. *Surg Laparosc Endosc Percutan Tech.* 2009 Dec;19(6):493-6.
- Kim HJ, Lee JI, Lee YS, Lee IK, Park JH, Lee SK, Kang WK, Cho HM, You YK, Oh ST. Single-port transumbilical laparoscopic appendectomy: 43 consecutive cases. *Surg Endosc.* 2010 Nov;24(11):2765-9.
- Oltmann SC, Garcia NM, Ventura B, Mitchell I, Fischer AC. Single-incision laparoscopic surgery: Feasibility for pediatric appendectomies. *J Pediatr Surg.* 2010 Jun;45(6):1208-12.
- Visnjic S. Transumbilical laparoscopically assisted appendectomy in children: High-tech low-budget surgery. *Surg Endosc.* 2008 Jul;22(7):1667-71.



Variations in Intraocular Pressure During Valsalva Manoeuvre

Sana Jahangir, Haroon Tayyab, Samina Jahangir, Akhwand Abdul Majeed Jawad and Muhammad Asif Bashir

ABSTRACT

Objective: To evaluate variation in intraocular pressure during Valsalva manoeuvre.

Methodology: This prospective study was conducted in Department of Ophthalmology, Sharif Medical & Dental College from January to March 2015. In fifty healthy volunteers, hundreds eyes were evaluated with Goldmann's applanation tonometer and their intraocular pressure was documented before and during Valsalva manoeuvre. All patients underwent complete ophthalmic examination and were excluded from the study if they had any of the factors mentioned in the exclusion criteria.

Results: The difference in IOP before and during valsalva was found to be statistically significant. The range of elevation was between 2.9 to 11 mm Hg. (p-value <0.001). Increase of greater than 5 mmHg was noted in 30 eyes.

Conclusion: Valsalva manoeuvre causes a significant rise in intraocular pressure but further studies are needed to evaluate the rise in IOP during valsalva as a risk factor for developing glaucoma.

Keyword: *Applanation Tonometer. Valsalva. Intraocular pressure. Glaucoma.*

INTRODUCTION

Glaucoma is the leading cause of irreversible blindness in the world. It affects more than 70 million people worldwide, with 10 % being bilaterally blind.¹ Glaucoma is the name given to a group of eye diseases in which optic nerve at the back of eye is slowly destroyed. In most people, this damage is due to an increased pressure inside the eye. Since reduction of intraocular pressure (IOP) is the only proven method to manage this disease, variations in this parameter is very important to monitor.

Some degree of psychological stress is experienced by patients when they visit the doctor.² Same is true for patients who are about to get their intraocular pressure tested and inadvertent breath holding can alter the the results of applanation tonometry.³ Some studies have been conducted to explore the variation in intraocular pressure with breath holding in various situations such as in high resistance instrument players and weight lifters.^{4,5}

Valsalva manoeuvre is considered a standard stimulus for investigation of cerebral and ocular blood flow.⁶ Previous studies have shown that pulsatile ocular blood flow is reduced during Valsalva and this reduction is proportional to rise in IOP.⁴

The rationale of this study was to monitor any changes in intraocular pressure after Valsalva manoeuvre. It is important to measure such changes because the therapeutic options and further intervention with patients with known glaucoma may change when encountering false intraocular pressure measurements. Patients may be prescribed additional medications or tests or their follow up routine with doctor may under go some revision on encountering falsely high intraocular pressure; and the treating physician may be unaware of unintentional Valsalva by the patient.

METHODOLOGY

The prospective study was conducted in Department of Ophthalmology, Sharif Medical & Dental College. This was a prospective study conducted over a period of three months from January to March 2015. Informed consent was taken from 50 healthy volunteers aged between 30 and 37 years and a total of 100 eyes were examined. Permission for this study was granted by Hospital Ethical Committee. All participants underwent a full ophthalmic examination including visual acuity, slit-lamp evaluation, IOP measurement by means of Goldmann's tonometer. Intraocular pressure was measured with Goldman Applanation Tonometer (GAT) before and during valsalva manoeuvre. Antibiotic drops were instilled after applanation tonometry. Subjects were excluded from the study if they had any physical disability that would prevent performing the required valsalva manoeuvre, systemic disease, spherical equivalent refractive error greater than ± 1.00 diopter, IOP greater than 24 mmHg by GAT, glaucoma, cup-disc ratio asymmetry, any kind of corneal disease, or use of systemic or topical

Sharif Medical & Dental College, Sharif Medical City,
Sharif Medical City Road, Off Raiwind Road, Jati Umra,
Lahore 54000, Pakistan.

Correspondence: Dr. Sana Jahangir
Assistant Prof. Eye Department
Sharif Medical & Dental College
E-mail: sanajahangir@gmail.com

Received: March 16, 2015; Accepted: May 8, 2015.

medications. All data are presented as mean \pm Standard Deviation (SD). During the evaluation of the study data, along with the descriptive statistical methods, parameters with normal distribution for the comparison of qualitative data were evaluated using paired samples t-test, 95% CI were determined and $p < 0.05$ was regarded as statistically significant. Statistical calculations were performed using the SPSS 11.5 statistical package.

RESULTS

Data of one hundred eyes of 50 patients was analysed. Mean age in years being 32 ± 1.5 and age range being 30 to 37 years. The difference between intraocular pressure before and during Valsalva was found to be statistically significant ($p=0.001$). The mean value for IOP elevation was 2.8 ± 3.1 mmHg during Valsalva manoeuvre, range of IOP elevation during this manoeuvre being 2.9 to 11mmHg. IOP elevation was noted in 86 eyes. Increase of greater than 5 mmHg was noted in 30 eyes whereas 3 eyes showed an IOP elevation of greater than 10 mmHg. IOP was measured on three consecutive Valsalva manoeuvre and final reading was the mean of three readings.

DISCUSSION

Valsalva is considered a standard stimulus for investigation of cerebral and ocular blood flow.⁶ Previous studies have shown that pulsatile ocular blood flow is reduced during Valsalva and this reduction is proportional to rise in IOP.⁴ There are four phases of the Valsalva manoeuvre.⁷ During phase 1, initiation, there is rise of arterial pressure as blood is squeezed from the thoracic aorta. In phase 2, raised intrathoracic pressure reduces venous return leading to a fall in mean arterial pressure. The rise in intrathoracic pressure is transmitted till the superior ophthalmic vein leading to a rise in episcleral venous pressure with resultant rise in intraocular pressure. Another mechanism for rise in IOP is choroidal engorgement and increase in choroidal volume.⁸ In phase 3, release of the glottis, restores venous return with a drop in intrathoracic pressure this restores mean arterial pressure. In phase 4, there is reflex bradycardia. Some studies have been previously conducted to study the effect of Valsalva on intraocular pressure. Oggel reported elevation in IOP during Valsalva in recumbent and erect position.⁹ In another study, increase of 7.2 mm Hg was reported during Valsalva manoeuvre.¹⁰ Healthy volunteer subjects were also evaluated for variation in IOP with Valsalva.³ Individual responses were variable with increase of upto 9.5mmHg and decrease of upto 4 mmHg. In another study, Lanigan also noted a rise in IOP during Valsalva with a mean rise of 7.2 mmHg from a mean baseline value of 12.8 mmHg.¹⁰

Apart from Valsalva, other factors have also been associated with changes in intraocular pressure like postural change, emotional status of patient, exercise and systolic blood pressure.¹¹⁻¹³

In this study, rise in intraocular pressure due to Valsalva was found to be statistically significant. Mean increase in IOP being 2.8 ± 3.1 mmHg. However, there was a wide range of IOP elevation. There are no studies as yet to determine whether rise in IOP during Valsalva is a risk factor for development of glaucoma. Further studies are needed to evaluate this.

CONCLUSION

Intraocular pressure can rise to various levels during intentional or unintentional Valsalva manoeuvre. Whether this momentary rise can adversely effect preexisting glaucoma or not, it can definitely give false readings than can mislead the treating physician. Therefore, we recommend that ophthalmologist should explain to the patient about possibility of unintentional Valsalva during IOP monitoring and should advice them to take breaths normally during the process of IOP measurement to avoid measurement discrepancy.

REFERENCES

1. Rao V, Doctor M, Rao G. Prevalence and prognosis of pseudoexfoliation glaucoma in Western India. *Asia Pac J Ophthalmol (Phila)*. 2015 Mar-Apr;4(2):121-7.
2. Brody S, Erb C, Veit R, Rau H. Intraocular pressure changes: The influence of psychological stress and the Valsalva maneuver. *Biol Psychol*. 1999 Oct;51:43-57.
3. Liu WC, Lee SM, Graham AD, Lin MC. Effects of eye rubbing and breath holding on corneal biomechanical properties and intraocular pressure. *Cornea*. 2011 Aug;30(8):855-60.
4. Schuman JS, Massicotte EC, Connolly S, Hertzmark E, Mukherji B, Kunen MZ. Increased intraocular pressure and visual field defects in high resistance wind instrument players. *Ophthalmology*. 2000 Jan;107(1):127-33.
5. Vieira GM, Oliveira HB, Andrade DT, Bottaro M, Ritch R. Intraocular pressure variation during weight lifting. *Arch Ophthalmol*. 2006 Sep;124(9):1251-4.
6. Kothe AC. The effect of posture on intraocular pressure and pulsatile ocular blood flow in normal and glaucomatous eyes. *Surv Ophthalmol*. 1994 May;38 Suppl:S191-7.
7. Korner PI, Tonkin AM, Uther JB. Reflex and mechanical circulatory effects of graded Valsalva maneuvers in normal man. *J Appl Physiol*. 1976 Mar;40(3):434-40.
8. Aykan U, Erdurmus M, Yilmaz B, Bilge AH. Intraocular pressure and ocular pulse amplitude variations during the Valsalva maneuver. *Graefes Arch Clin Exp Ophthalmol*. 2010 Aug;248(8):1183-6.

9. Oggel K, Sommer G, Neuhann T, Hinz J. Variations of intraocular pressure during Valsalva's manuevre in relation to body position and length of bulbus in myopia. *Graefes Arch Clin Exp Ophthalmol*.1982;218(1):51-4.
10. Lanigan LP, Clark CV, Hill DW. Intraocular pressure responses to systemic autonomic stimulation. *Eye (Lond)*.1989; 3: (Pt4):477-83.
11. Liu W, Xing X, Ji J. Posture change and intraocular pressure fluctuation. *Zhonghua Yan Ke Za Zhi*. 2015 Feb;51(2):146-50.
12. Hamilton-Maxwell KE, Feeney L. Walking for a short distance at a brisk pace reduces intraocular pressure by a clinically significant amount. *J Glaucoma*. 2012 Aug;21(6):421-5.
13. Schmidl D, Werkmeister R, Garhöfer G, Schmetterer L. Ocular perfusion pressure and its relevance for glaucoma. *Klin Monbl Augenheilkd*. 2015 Feb;232(2):141-6.



Comparison of Conventional and Minimal Invasive Dynamic Hip Screw Technique

Waqas Ali, Farooq Azam Khan and Khalid Mehmood

ABSTRACT

Objective: To compare clinical outcome of minimally invasive dynamic hip screw technique with conventional dynamic hip screw technique in terms of incision length, peroperative hemoglobin level drop, need of blood transfusions and fracture union in patients sustaining Boyd and Griffin type 1 & 2 intertrochanteric fractures.

Methodology: In this randomized controlled trial, total number of seventy patients with intertrochanteric fracture were treated with either conventional dynamic hip screw (Group A) or minimally invasive dynamic hip screw technique (Group B). They were randomized into two groups with 35 patients in each group. All patients were operated by a single surgeon. One group was managed by minimally invasive dynamic hip screw and the other with conventional dynamic hip screw.

Result: Each group contained 35 patients. The conventional dynamic hip screw group had significantly larger wound incision (p-value = 0.001), greater hemoglobin drop (p-value = 0.001) and a more frequent need of blood transfusion (p-value = 0.006) as compared to the minimally invasive dynamic hip screw Group. There was no significant difference in terms of union rates and all the fractures healed within six months time.

Conclusion: This study concluded that minimal invasive dynamic hip screw technique requires smaller incision, less hemoglobin level drop and less need for blood transfusion as compared to conventional dynamic hip screw technique and there is no significant difference in terms of bone union between these two techniques. Hence minimal invasive DHS technique is effective, better and safe as compared to conventional DHS.

INTRODUCTION

Intertrochanteric fracture is the most frequently seen fracture in orthopaedic accident and emergency department; also known as fractures of proximal femur or hip. Mostly, patients of older age group are affected, but younger patients may be involved as well if there is high energy trauma.¹

These intertrochanteric fractures constitute nearly 50% of all hip and proximal femur fractures. Accident and Emergency data showed 250,000 such fractures in 1990 alone and it is expected to double by the end of year 2040, accounting for an estimated 16 billion US dollars for treatment annually.²

The standard of care for intertrochanteric fracture is by reduction and internal fixation. The gold standard choice of implant is dynamic hip screw (DHS) because of its time tested surgeon preference and reliability,^{4,6} but the conventional surgery requires longer incision and associated more blood. These problems have led us establish a minimally invasive and less traumatic technique for the treatment of intertrochanteric fractures.²

Intramedullary nails are another choice that can be utilised for minimally invasive surgery but their downside is higher cost. A study comprising of 206 patients showed no superiority for Proximal Femoral nail (PFN) when compared to sliding hip screw as there was no significant clinical or radiological difference in final outcome but cost of intramedullary implants remained twice as high as that of sliding hip screws.^{7,8}

Recently, various studies have documented effective minimally invasive surgery technique in DHS fixation for Intertrochanteric fractures instead of conventional technique comprising of longer incision.⁹⁻¹⁴

In another study, it was concluded that reduction of fracture was nearly identical in both techniques and there was complete healing/union of all fractures in six months. However, minimally invasive DHS (MIDHS) technique did better in terms of length of skin incision, preoperative blood loss and post operative rate of blood transfusions when compared to conventional DHS (CDHS).¹⁰ Furthermore, minimally invasive technique requires no additional equipment.⁷ Due to these shortcomings of CDHS, the technique of minimally invasive surgery has received enormous attention recently. So, minimally invasive surgery offers advantages of faster rehabilitation as well as better cosmetic results.¹⁵

The rationale of this study is to determine outcome of minimally invasive DHS (MIDHS) technique compared to the conventional DHS (CDHS) technique in terms of incision length, per-operative haemoglobin level drop, need of blood transfusion and bone union.

Sharif Medical and Dental College
Sharif Medical City Road, Off Raiwind Road, Jati Umra,
Lahore 54000, Pakistan.

Correspondence: Dr. Khalida Ahtesham
Assistant Prof. of Histopathology Department of Pathology
Sharif Medical and Dental College
E-mail: drkhalidahtesham@yahoo.com

Received: March 16, 2015; Accepted: May 16, 2015.

As there is no data or study available in our setup, this study will provide a base line data. This technique will provide advantages of early mobilization and fast rehabilitation to the patients.

METHODOLOGY

It was randomized Controlled Trial conducted in Department of Orthopaedics, Jinnah Hospital, Lahore from January 2013 to October 2013. Sample size of 70 cases (35 in each group) was calculated with 80% power of test and 1% level of significance.

Sample size of 70 cases (35 in each group) was calculated with 80% power of test, 1% level of significance and taking expected percentage of blood transfusion in both groups i.e. 7.14% in minimally invasive DHS group versus 40% in Conventional DHS group in patients with Intertrochanteric fractures of Boyd and Griffin type 1 & 2.

Inclusion Criteria

1. Age between 50 to 75 years
2. Both genders
3. Intertrochanteric fractures of Boyd & Griffin type 1 & 2, presenting within two weeks after injury.

Exclusion Criteria

1. Dementia and other psychiatric illnesses (e.g. manic disorder, depression assessed on history)
2. Inability to walk before fracture (assessed on history)
3. Pathological fractures (assessed on history and evaluation of X-Rays)
4. Open fractures (assessed on history and examination)
5. Patient with diabetes mellitus, hypertension, ischemic heart disease, end stage renal disease, or receiving steroids/chemotherapy (assessed on history and pre-operative workup).

Seventy patients fulfilling inclusion criteria were enrolled from Out Patient and Emergency department after informed consent and approval of hospital ethical committee. Patients were assigned to group A & B by random number table (35 in each group). Procedure was explained and follow up plan was made and discussed with patient. The demographic information including age, sex and address was collected and documented. Patient were initially managed with skin traction. All patients were planned to receive surgical treatment of the fracture with same implant and same surgeon. Group A was operated by conventional DHS technique while group B was operated by minimally invasive DHS technique.

All patients were checked for drop in hemoglobin, need for blood transfusion and incision length on 1st postoperative day. Time of union and weight bearing was assessed and documented as other variables on

outdoor follow-ups after discharge. All the information was collected and registered on the designed proforma. The Data was entered and analyzed using SPSS 17. The quantitative variables like age, incision length and Hb level were expressed as mean \pm SD, while qualitative variable like blood transfusion was expressed in frequency and percentages. Chi-square test was used to compare blood transfusion and union in both groups. A p-value less than or equal to 0.05 will be taken as statistical significant and t-test was used to compare incision length and haemoglobin level in both groups.

RESULTS

Mean age was 62.5 years in both the groups (Figure 1). Overall, 70% were male patients and 30% were female. Gender distribution in Group A and B is shown in Figure 2.

Out of 70 patients, 43 patients (61.43%) had Boyd & Griffin Type I fracture and 27 (38.57%) had Type II fracture. In CDHS group 62.8% presented with Type I fractures as compared to 60% in MIDHS Group. Whereas in CDHS group 37.2% presented with Type II fractures as compared to 40% in MIDHS Group. All patients were assessed for incision length, hemoglobin drop and need of blood transfusion on the 1st post operative day.

The mean incision length for group A (CDHS) was 10.9 ± 1.98 cm whereas for group B (MIDHS) it was 3.7 ± 0.44 cm. The incision length was significantly different in both groups having p-value=0.001. Average Hb drop was 2.15 ± 1.9 g/dl in group A (CDHS) and 0.72 ± 0.18 g/dl in group B (MIDHS). This average Hb level drop showed significantly less (p-Value=0.001) in MIDHS group as compared to CDHS group.

The blood transfusion rate was markedly higher in CDHS group when compared to MIDHS group. In group A (CDHS) 40% patients required blood transfusion as compared to 11% in group B (MIDHS). A significant p-value=0.006 was observed in this variable.

All the fractures were healed within six months from the operation. There was no significant difference (p-value=0.23) in bone union time in both groups. Around 85.7% fractures united within 9-16 weeks in group A (CDHS) as compared to 94.3% in group B (MIDHS). Very few fractures healed in 17-24 weeks time i.e. 14.3% in group A (CDHS) and 5.7% in group B (MIDHS). A bar graph representation of union in both groups is shown in Figure 3.

All results are summarized in Table 1.

Table 1: Results of variables with p-value

Variable	Group A (CDHS)	Group B (MIDHS)	p-value
Incision length	10.99 ± 1.98	3.7 ± 0.44	0.001
Hb drop	2.15 ± 1.9	0.72 ± 0.18	0.001
Need of transfusion	40	11	0.006
Union of bone	9-16 weeks	85.7	0.232
	17-24 weeks	14.3	

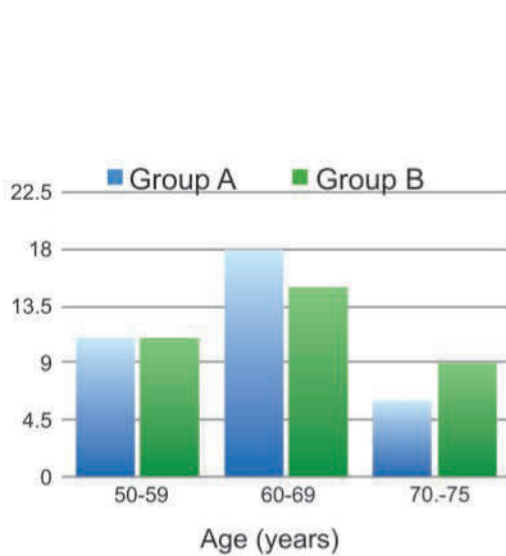


Figure 1: Graph showing age distribution of both groups

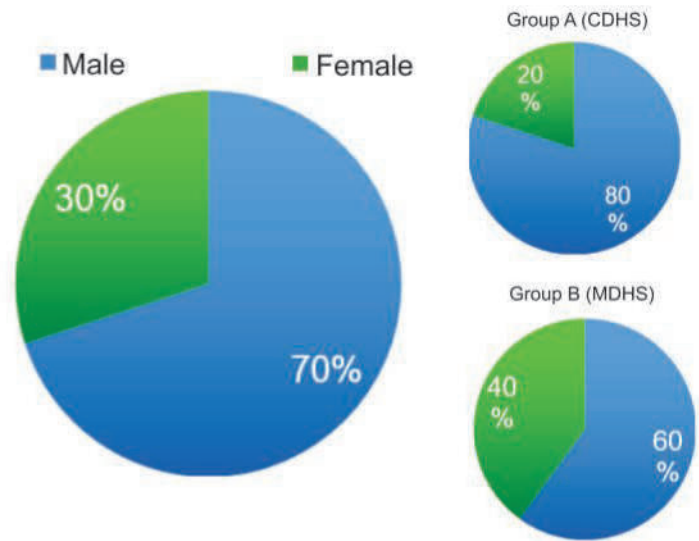


Figure 2: Gender distribution Pie chart

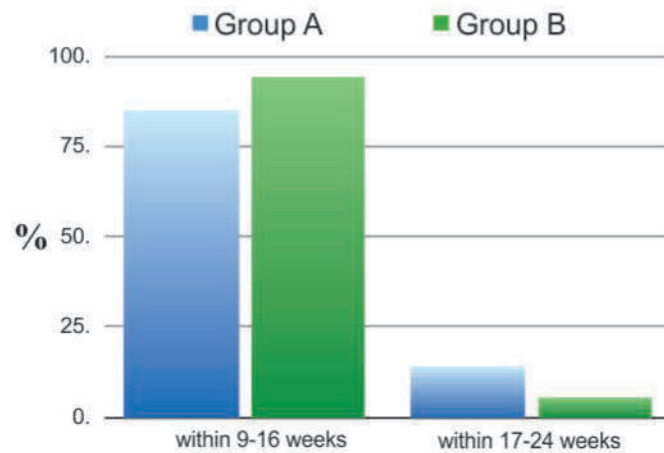


Figure 3: Comparison of union time in both groups

DISCUSSION

Intertrochanteric fractures are one of the commonest fractures encountered in orthopaedic department. Many devices have been used to achieve stable fixation and union but the use of DHS remains the most preferred method. This procedure provides rigid fixation and allows early weight bearing. Conventional DHS technique has greater morbidity due to larger exposure and blood loss, therefore minimally invasive technique has been devised to overcome such morbidity. This study has compared C-DHS with MI-DHS in terms of incision size, blood loss and need of transfusion.

In this study a total of 70 patients with intertrochanteric fracture (Boyd & Griffin Type I and II) were included and they were divided in two groups each containing 35 patients.

Mean age of patients was 62.5 years in both the groups. Similar results were shown in a study carried out in Department of Orthopaedic Khyber Teaching Hospital, Peshawar.¹⁶ However a study conducted by Wong showed mean age of 80.6 ± 7.6 years.¹⁵ Similarly, a study carried out in Greece showed that mean age for patients suffering from Intertrochanteric fractures was 81.03 ± 6.38 .¹⁷

This study showed that overall 70% of the patients were male. In C-DHS group 80% patients were male compared to MI-DHS group in which 60% patients were male. However, a study carried out in Spain clearly showed that incidence of intertrochanteric fractures is more in females as compared to male population.¹⁸ Similarly a study carried out in France also presented that these fracture were much more common in females.¹⁹

According to this study, out of 70 patients, 43 patients (61.43%) had Boyd & Griffin Type I fracture and 27 (38.57%) had Type II fracture which is in contrast to a study carried out in India where Boyd & Griffin Type II fractures were more common than type I.²⁰

All the patients were assessed for incision length, haemoglobin drop and need of blood transfusion on the 1st post operative day. Our results showed that the mean incision length for group A (C-DHS) was 10.9 ± 1.98 cm whereas for group B (MI-DHS) it was 3.7 ± 0.44 cm. Same results were shown in a study carried out in Taiwan where mean incision for C-DHS was 9.5 ± 2.6 cm and 3.0 ± 0.21 cm for MI-DHS group (p-value < 0.001).¹⁰ A study conducted in West China showed similar results to our study in which MI-DHS group incision was significantly shorter than the conventional group.²¹ Another study conducted in Italy concluded that average incision length was significantly smaller in MI-DHS group as compared to C-DHS Group (p-value < 0.001).²²

According to this study the average hemoglobin Drop was 2.15 ± 1.9 g/dl in group A (C-DHS) and 0.72 ± 0.18 g/dl in group B (MI-DHS). This average Hb drop showed statistically significant p-Value (0.001) in MI-DHS group as compared to C-DHS group. A study conducted in China is comparable to this study in terms of more hemoglobin drop in C-DHS patients. Here the hemoglobin loss in C-DHS group was 2.6 ± 1.1 g/dl whereas in MI-DHS group Hb loss was 1.4 ± 1.0 g/dl.¹⁵ However, a study conducted in France showed that the mean hemoglobin loss in C-DHS patients was 1.37 ± 0.98 .¹⁹ Micheal conducted a study which showed that the average blood loss in MI-DHS screw was 1.18 ± 1.0 g/dl whereas in C- DHS it was 2.4 ± 1.0 g/dl.⁹ Similar results of lower blood loss were observed in a study conducted in Shanghai Sixth People's Hospital.²³

In this study the blood transfusion rate was markedly higher in C-DHS group as compared to MI-DHS group. A significant p-value (0.006) was observed in this variable. These results have close concordance with other studies carried out by Wang. Their results showed that blood transfusion rates were significantly lower in minimally invasive DHS group as compared to conventional DHS.²¹

Although two patients experienced wound complication (superficial wound infection) in C-DHS group and one patient in MI-DHS group which was successfully treated with antibiotics. In this study, all the fractures healed within six months from the operation. There was no significant difference (p-value=0.23) in bone union time in both groups. Around 85.7% fractures united within 9-16 weeks in group A (C-DHS) as compared to 94.3% in group B (MI-DHS). Very few fractures healed in 17-24 weeks time i.e; 14.3% in group A (C-DHS) and 5.7% in group B (MI-DHS). This study is comparable to a study carried out in Department of Orthopedic Surgery, Taipei City Hospital. The results of that study showed bone union within six months and there was no significant difference (p-value=0.38) between MI-DHS and C-DHS group.¹⁰ Slightly different results were obtained in a study conducted in China where all fractures healed within four months.²¹ However, in contrast to this study another study done in china showed faster fracture healing in MI-DHS group.²³

The limitations of this study were that we have not included Boyd & Griffin III and IV. Therefore results of these fractures were out of spectrum of this study. Another limitation in current study was that no comorbid condition had been included. This limitation is important because significant number of patient presented with such fractures belonging to elderly age group.

Minimal Invasive surgery (MIS) is becoming

increasingly popular in all fields of surgery including orthopaedics. Different conventional orthopaedic operative procedures can be done safely by using MIS technique. Recent studies have showed that this minimally invasive technique is associated with decreased bleeding, post operative pain, reduced post operative morbidity and earlier return to function.

CONCLUSION

Minimal invasive DHS technique requires smaller incision, less hemoglobin level drop and less need for blood transfusion as compared to Conventional DHS technique and there is no significant difference in terms of bone union between these two techniques.

Hence, Minimal Invasive DHS technique is effective, better and safe as compared to Conventional DHS.

REFERENCES

- Hutchings L, Fox R, Chesser T. Proximal femoral fractures in the elderly: How are we measuring outcome? *Injury*. 2011 Nov;42(11):1205-13.
- Sawaia RN, Belangero WD. The treatment of transtrochanteric fractures of the femur with a minimally invasive technique using an extramedullary implant MINUS System. *Int Orthop*. 2008 Apr;32(2):159-65.
- Cummings SR, Rubin SM, Black D. The future of hip fractures in the United States: Numbers, costs, and potential effects of postmenopausal estrogen. *Clin Orthop Relat Res*. 1990 Mar;(252):163-6.
- Sheng WC, Li JZ, Chen SH, Zhong SZ. A new technique for lag screw placement in the dynamic hip screw fixation of intertrochanteric fractures: Decreasing radiation time dramatically. *Int Orthop*. 2009 Apr;33(2):537-42.
- Alobaid A, Harvey EJ, Elder GM, Lander P, Guy P, Reindl R. Prospective randomized trial of two techniques of insertion of a standard dynamic fixation device. *J Orthop Trauma*. 2004 Apr;18(4):207-12.
- McLoughlin SW, Wheeler DL, Rider J, Bolhofner B. Biomechanical evaluation of the dynamic hip screw with two- and four-hole side plates. *J Orthop Trauma*. 2000 Jun-Jul;14(5):318-23.
- Waters TS, Gibbs DM, Dorrell JH, Powles DP. Percutaneous dynamic hip screw. *Injury*. 2006 Aug;37(8):751-4.
- Saudan M, Lübbecke A, Sadowski C, Riand N, Stern R, Hoffmeyer P. Pertrochanteric fractures: Is there an advantage to an intramedullary nail? A randomized, prospective study of 206 patients comparing the dynamic hip screw and proximal femoral nail. *J Orthop Trauma*. 2002 Jul;16(6):386-93.
- Ho M, Garau G, Walley G, Oliva F, Panni AS, Longo UG, Maffulli N. Minimally Invasive dynamic hip screw for fixation of hip fractures. *Int Orthop*. 2009 Apr;33(2):555-60.
- Lee YS, Huang HL, Lo TY, Huang CR. Dynamic hip screw in the treatment of intertrochanteric fractures: A comparison of two fixation methods. *Int Orthop*. 2007 Oct;31(5):683-8.
- Alobaid A, Harvey EJ, Elder GM, Lander P, Guy P, Reindl R. Minimally invasive dynamic hip screw: Prospective randomized trial of two techniques of insertion of a standard dynamic fixation device. *J Orthop Trauma*. 2004 Apr;18(4):207-12.
- DiPaola M, Rozbruch SR, Helfet DL. Minimal incision technique using a two-hole plate for fixation of stable intertrochanteric hip fractures. *Orthopedics*. 2004 Mar;27(3):270-4.
- Gotfried Y. Percutaneous compression plating for intertrochanteric hip fractures: Treatment rationale. *Orthopedics*. 2002 Jun;25(6):647-52.
- Egol KA. Minimally invasive orthopaedic trauma surgery: A review of the latest techniques. *Bull Hosp Jt Dis*. 2004;62(1-2):6-12.
- Wong TC, Chiu Y, Tsang WL, Leung WY, Yeung SY. A double-blind, prospective, randomised, controlled clinical trial of minimally invasive dynamic hip screw fixation of intertrochanteric fractures. *Injury*; 2009 Apr;40(4):422-7.
- Khan N, Askar Z, Ahmed I, Durrani Z, Khan MA, Hakeem A, Faheemullah. Intertrochanteric fracture of femur; outcome of dynamic hip screw in elderly patients. *Professional Med J*. Jun 2010; 17(2): 328-33.
- Verettas DA, Ifantidis P, Chatzipapas CN, Drosos GI, Xarchas KC, Chloropoulou P, Kazakos KI, Trypsianis G, Ververidis A. Systematic effects of surgical treatment of hip fractures: Gliding screw-plating vs intramedullary nailing. *Injury*. 2010 Mar;41(3):279-84.
- Alvarez-Nebreda ML, Jiménez AB, Rodríguez P, Serra JA. Epidemiology of hip fracture in the elderly in Spain. *Bone*. 2008 Feb;42(2):278-85.
- Foulongne E, Gilleron M, Roussignol X, Lenoble E, Dujardin F. Mini-invasivenailversusDHS to fixperthrochanteric fractures: a case-control study. *Orthop Traumatol Surg Res*. 2009 Dec;95(8):592-8.
- Jabshetty AB. Management of intertrochanteric fracture by DHS fixation. *Ind J Sci Tech*. 2011;4:1681-84.
- Wang JP, Yang TF, Kong QQ, Liu SJ, Xiao H, Liu Y, Zhang H. Minimally invasive technique versus conventional technique of dynamic hip screws for intertrochanteric femoral fractures. *Arch Orthop Trauma Surg*. 2010 May;130(5):613-20.
- del Prete F, Nizegorodcew T, Regazzoni P. Quantification of surgical trauma: Comparison of conventional and minimally invasive surgical techniques for pertrochanteric fracture surgery based on markers of inflammation (interleukins). *J Orthop Traumatol*. 2012 Sep;13(3):125-30.
- Cheng T, Zhang G, Zhang X. Review: Minimally invasive versus conventional dynamic hip screw fixation in elderly patients with intertrochanteric fractures: A systematic review and meta-analysis. *Surg Innov*. 2011 Jun;18(2):99-105.



Case Report

Minimal Surgical Intervention in Infected Necrotizing Pancreatitis: An Experience of Laparoscopic Pancreatic Necrosectomy at Sharif Medical City Hospital, Lahore

Ahsen Nazir Ahmed, Muhammad Saad Faisal and Muhammad Adnan Khan

ABSTRACT

A 30 years old female presented with a few days history of severe upper abdominal pain, jaundice, fever, tachycardia, dehydration and respiratory discomfort. She had past history of acute cholecystitis. On laboratory and radiological investigations, a diagnosis of infected pancreatic necrosis was established and surgery was planned for management of this condition. Laparoscopic pancreatic necrosectomy was performed successfully in this patient by approaching pancreas through gastrocolic ligament for debridement of necrotic tissue at its tail. Peritoneal lavage and drainage was performed by putting drains in lesser sac and pelvic cavity. After this laparoscopic surgery, patient showed tremendous recovery. Later on, laparoscopic cholecystectomy were performed in her follow up period.

Key words: *Infected pancreatic necrosis. Laparoscopic pancreatic necrosectomy. Lesser sac. Gastrocolic ligament.*

INTRODUCTION

Acute pancreatitis (AP) is usually a self-limiting disease that is expected to resolve spontaneously without serious complications. However, 25% of patients with AP will end up with the development of potentially life threatening complications like necrosis of the pancreatic parenchyma, the peripancreatic tissue or both.¹ Such patients are at risk of infection, multiple system organ failure and even death. Sometimes, surgical intervention (debridement of necrotic tissue) is required to reduce high morbidity and mortality. However, the outcome of operative treatment of AP may lead to surgical stress on the patient causing lots of events that can complicate the management.²

Over the last decade, laparoscopic surgery has proven to be an effective and less traumatic option in the management of many surgical problems. Hence, with all its advantages, laparoscopic surgery can be an efficient alternative to minimize the surgical trauma and to accelerate the recovery process in the management of AP. Here, we report a first case of AP complicated with pancreatic necrosis, managed successfully with laparoscopic surgical technique.

Case report

A 30 years old female presented with complaints of severe pain in abdomen radiating to back, fever and respiratory discomfort for last few days. When asked

about the previous history, she revealed that she had three previous episodes of right hypochondrial pain, for which she had to be admitted in hospital twice over a period of one year. She did not have any associated medical conditions. She was admitted in the hospital for further work up and management.

At admission, she had temperature of 101°F, pulse rate of 115/ min, blood pressure 105/68 mmHg, and respiratory rate of 23/ min. She also had mild jaundice and signs of dehydration. Abdominal examination revealed tenderness in the upper abdomen, more in epigastric region and bowel sounds were audible. Initially, a conservative plan was suggested for her. She was given intravenous fluids, analgesics, and broad spectrum antibiotics. The initial laboratory investigations showed raised total leukocyte count (19.4 /mm³), serum bilirubin level (2.4 mg/ dL) and raised serum amylase (5687 IU). On ultrasonography, there were multiple tiny small gall stones with sludge present in the hepatobiliary tract. Also her pancreas was swollen pancreas with mild dilatation of the its duct and presence of pancreatic debrinous fluid. There was moderate amount of debrinous ascites in the abdomen and pelvis. On routine chest X-ray, there was bilateral obliteration of costophrenic and costodaphragmatic angles. The patient was managed for another 24 hours on conservative treatment. Her condition did not improve with conservative management and her dyspnea and fever worsened. Her computerized tomography (CT) scan showed the presence of necrotic tissue in the tail of pancreas. She was planned to receive surgical intervention. A laparoscopic approach for surgery was adopted.

The patient was placed in French position. Operating surgeon stood between the legs of the patient. Camera assistant on right side while first assistant and scrub nurse stood on left side of the patient. Monitor was

Sharif Medical & Dental College, Sharif Medical City,
Sharif Medical City Road, Off Raiwind Road, Jati Umra,
Lahore 54000, Pakistan.

Correspondence: Dr. Ahsen Nazir Ahmed
Associate Prof. Department of Surgery
Medical & Dental College
E-mail: drannahmed@hotmail.com

Received: March 16, 2015; Accepted: May 11, 2015.

positioned over left shoulder of the patient, closer to midline. Pneumoperitoneum was created after insertion of 10 mm optical trocar infra umbilically. Diagnostic laparoscopy was performed. Two lateral para rectal trocars were inserted under vision (Figure 1).

Peripancreatic adhesions were released with blunt dissection. Then we had to insert another epigastric trocar for holding the stomach. We accessed the pancreatic necrotic tissue by a trans mesocolic approach. We first mobilized the inflammatory phlegmon formed by stomach, colon, mesocolon and pancreas itself (Figure 2). Pancreas was approached through lesser sac by creating a window in gastrocolic ligament. The dead necrotic tissue was identified at the tail of pancreas and was taken out as chips with help of Harmonic scalpel and grasper.

The chips were collected in a pouch made of surgical gloves. One drain in lesser sac and other in the pelvis were placed after peritoneal lavage. Closure was done with prolene sutures.

Postoperatively, the patient was managed in the intensive care unit for first 24 hours and then shifted to surgical ward. She was mobilized after 8 hours. Her fever and tachycardia settled within 24 hours. She was allowed oral diet within 48 hours. Foley's catheter and drains were removed after 48 hours and she was discharged at 5th post operative day. Her first follow up visit was planned after 5 days which was unremarkable. She also underwent laparoscopic cholecystectomy later in the course of her follow up.

DISCUSSION

Management of necrotizing or infective pancreatitis is always demanding and quite often, a multi disciplinary approach is required. Most of the time, surgical intervention is the solution. The diseased retro peritoneum is treated as an abscess

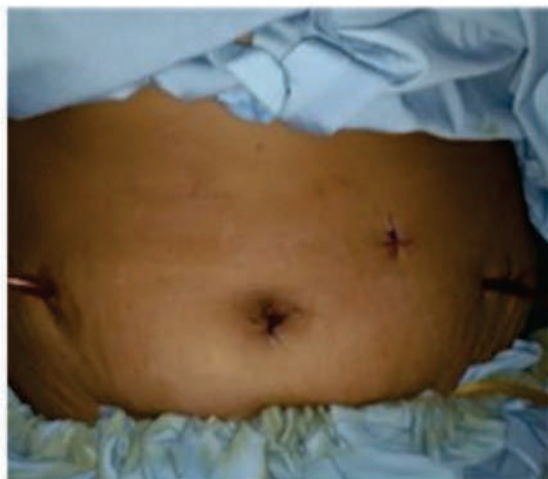

Figure 1: laparoscopic pancreatic necrosectomy: ports sites and drains.

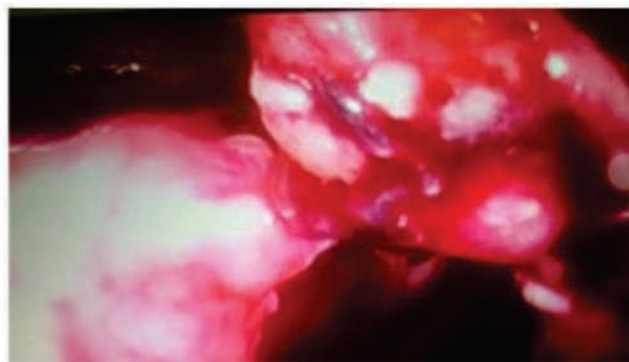


Figure 2: Access to pancreas in lesser sac through gastro colic ligament.

cavity with the aim of debridement of necrotic tissue of the pancreas. Although, treatment of infective pancreatitis has improved over several decades, the morbidity and mortality is still very high. Utilizing open surgical techniques, debridement of necrotic area of the pancreas is done with finger dissection and multiple drains are left in situ for irrigation and drainage. Later on, the peritoneal cavity is lavaged extensively to manage leakage from pancreatic tissue and to allow the continuous flow of infected and necrotic material.³ Over the last few years, laparoscopy had come up with advantages of less operative trauma, less pain and reduced postoperative hospitalization. With these benefits, surgeons are using laparoscopy for treatment of infective pancreatic necrosis. Laparoscopic approach adopts the same principles of open surgery i.e. debridement of necrotic tissue and irrigation of peritoneal cavity.

We adopted laparoscopic approach in this patient, keeping in view that minimal trauma may result in better outcome in terms of less postoperative pain, early recovery and better cosmesis. All of these benefits were achieved in this patient. Her fever, tachycardia and pain settled down within 2 days of intervention.

We used conventional 0° telescope and ultrasound energy device (Harmonic scalpel) for dissection of the tissue. Harmonic scalpel served to cut and seal at the same time, so the chances of hemorrhage were minimal.

Cuschieri in 2002, described for the first time, the technique of laparoscopic infracolic necrosectomy with irrigation of the lesser sac as a valid alternative to open necrosectomy.⁴ Ammori reported a case of pancreatic necrosectomy managed by laparoscopic transgastric approach.⁵ The patient made an uneventful recovery and was asymptomatic after two months of follow up.

The laparoscopic approach has been demonstrated to be safe and feasible in our patient. We completed the procedure within 104 minutes without significant intra operative and post operative complications. The key manoeuvre in this procedure was creation of window

in the lesser sac, through the gastrocolic ligament, so that the instruments could be advanced up to the pancreas. We needed a fourth port which helped to suspend the stomach upward and in creation of window in lesser sac.

CONCLUSION

The laparoscopic approach for pancreatic necrosectomy is feasible and safe. This technique helps in improving outcomes in terms of less pain, early recovery and better cosmesis. However, we need more trials before making any recommendations.

REFERENCES

1. Doctor N, Agarwal P, Gandhi V. Management of severe acute pancreatitis. *Indian J Surg*. 2012 Feb;74(1):40-6.
2. Babu BI, Sheen AJ, Lee SH, O'Shea S, Eddleston JM, Siriwardena AK. Open pancreatic necrosectomy in the multi disciplinary management of post inflammatory necrosis. *Ann Surg*. 2010 May;251(5):783-6.
3. Besselink MG, de Bruijn MT, Rutten JP, Boermeester MA, Hofker HS, Gooszen HG. Dutch Acute Pancreatitis Study Group. Surgical intervention in patients with necrotizing pancreatitis. *Br J Surg*. 2006 May;93(5):593-9.
4. Cuschieri A. Pancreatic necrosis: Pathogenesis and endoscopic management. *Semin Laparosc Surg*. 2002 Mar;9(1):54-63.
5. Ammori BJ. Laparoscopic transgastric pancreatic necrosectomy for infected pancreatic necrosis. *Surg Endosc*. 2002 Sep;16(9):1362.



A Rare Case of Disseminated Synovial Chondromatosis of Knee Joint: A Case Report

Farooq Azam Khan, Abbas Khan Bajwa and Syed Saqib Raza

ABSTRACT

Synovial chondromatosis is a benign tumor of synovium. However, it can be very destructive and can lead to osteoarthritis and pain. We report the first known case of an extensive presentation of this pathology of the knee joint. A 35-years-old male presented with left knee pain, swelling and stiffness caused by diffuse intra-articular and extra-articular synovial chondromatosis. After careful preoperative imaging and planning, he was followed by an open procedure of synovectomy in order to completely eradicate the disease. He regained full range of movement afterwards and reported improvement of his symptoms. Although synovial chondromatosis is described as a benign disease, it can be very destructive sometimes. It needs synovectomy to eradicate the disease completely.

Key words: *Synovial chondromatosis. Benign tumor. Synovectomy.*

INTRODUCTION

Synovial chondromatosis is a benign tumor that results from transformation of synovium to chondrocytes.¹ The aetiology of this disease is still unknown. It is divided into early, transitional and late phases. In earlier stages, there is active intra synovial disease without any loose bodies however in the later stages, multiple loose bodies are formed and intra synovial disease subsides.²

The disease commonly affects a single joint and knee is most commonly affected. However hip, shoulder and other synovial joints are also involved as well.³ It occurs more commonly in male patients during the third to fifth decades. A patient with synovial chondromatosis presents with joint stiffness, decreased range of motion, palpable swelling, crepitus and effusion.⁴

The disease is usually intra articular but can also be extra articular.⁵ In this case report, we describe a patient with both intra and extra-articular involvement of the knee joint with synovial chondromatosis.

Case Report

A 35-years-old man presented with eight-month history of progressive left knee pain with associated swelling. The pain occurred at rest, as well as during weight bearing; however it worsened in the later situation. The patient had restricted his walk to short distances. His knee had become increasingly swollen over a period of time. There was no history of night pain, locking and giving way of his knee. The patient was otherwise healthy. His medical history was insignificant and he

was only taking paracetamol for the pain relief.

On examination, the patient was seen to have significant quadriceps wasting of his left lower limb and a visibly swollen knee. On palpation, the swelling was firm to hard, non-mobile, well defined and measured 8 × 12 cm. There was no tenderness and associated skin changes. However, the patient had tenderness over the medial joint line. The extension was normal but flexion was restricted to 110 degrees. There was no ligamentous instability and rest of the knee joint examination was normal. The examination of hip joint was normal as well. A plain radiograph of the knee showed multiple calcific densities within the soft tissues surrounding it. The majority of these densities appeared to be outside the capsule. These appearances were initially thought to be idiopathic tumoral calcinosis. A magnetic resonance imaging (MRI) scan was advised for the detailed intra articular as well extra articular pathology. It showed thickening of the synovium, multiple intra-articular calcific and ossified loose bodies, and a large calcified bursa. The bursal component extended into the distal thigh and his proximal calf as well. These findings were consistent with synovial chondromatosis.

The patient's blood tests were within normal limits: Serum corrected calcium was 2.48 mmol/l, parathyroid hormone level was 2.4 pmol/l, inorganic phosphate was 1.20 mmol/l, serum urate was 306 μmol/l, white cell count of 8.6 × 10⁹/l, C-reactive protein of 3 mg/l and an ESR of 25 mm per hour.

An open procedure was planned following the findings of the MRI scan. A synovectomy with debridement and excision of these calcific bodies was performed.

A histological review at our histopathology laboratory confirmed the diagnosis of synovial chondromatosis. The sections demonstrated clusters of chondrocytes with focal ossification and the synovium overlying the nodules was thickened.

After the surgery, the patient underwent weekly physiotherapy sessions which were focused on

*Sharif Medical & Dental College, Sharif Medical City,
Sharif Medical City Road, Off Raiwind Road, Jati Umra,
Lahore 54000, Pakistan.*

*Correspondence: Dr. Farooq Azam Khan
Assistant Prof. Department of Orthopaedics
Sharif Medical & Dental College
E-mail: dr:farooq224@hotmail.com*

Received: March 16, 2015; Accepted: May 18, 2015.

strengthening the quadriceps. Along with physiotherapy, he was also advised to do isometric quadriceps strengthening exercises. He recovered well and has regained full range of motion in the affected knee with flexion increased to 130° over a period of two months. However, he has residual medial joint line tenderness due to early degenerative changes.

DISCUSSION

There are no cartilage cells inside the synovial membrane. It is therefore considered as metaplastic change of the synovial cells into chondrocytes in case of synovial chondromatosis. The exact aetiology is unknown.⁴ These chondrocytes eventually disperse into the joint as loose bodies.⁶

The combination of intra and extra-articular disease described in our case is an extremely rare condition. The initial radiograph showed extra-articular calcification. Therefore, idiopathic tumoral calcinosis was also thought as one of the differentials. However, this entity mostly affects people from Africa and the Caribbean in their second decade of life and has bilateral involvement. It affects multiple sites, and is very rarely intra-articular.⁷ Therefore, MRI scan was performed and it showed a single lesion with an intra-articular component. Disseminated synovial chondromatosis was a more likely diagnosis. Histopathology confirmed our diagnosis.

Extra-articular diseases can be further classified as tenosynovial chondromatosis or bursal chondromatosis.⁸ Only two patients have been reported in the literature with this pattern of disease in the knee.^{5,9} This raises concerns regarding a possible transformation into a malignant tumor; synovial chondrosarcoma. However, histological examination showed no significant nuclear atypia; thus malignancy was ruled out. The literature reports few cases of malignant transformation of synovial chondromatosis.⁶ In all of these cases, there was recurrence of benign disease later followed by transformation into malignant disease.

The extent of the disease and the presence of early degenerative arthritis also presented a challenging management problem. The combination of synovial chondromatosis and osteoarthritis is a finding in the late stages of the disease. Primary synovial chondromatosis over a period of time can lead to cartilage degeneration by mechanical wear and nutrient deprivation to the articular cartilage.³ There is no role of radiotherapy and chemotherapy in synovial chondromatosis and surgical excision is the treatment of choice.⁴ In cases of localized intra-articular disease, complete excision of the abnormal synovium seems to eradicate the disease. Generalized intra-articular disease with pain and

swelling justifies total synovectomy and removal of the loose bodies. In extra-articular disease the aim of treatment is complete excision.¹⁰

The patient also had early degenerative changes of knee joint. These changes and symptoms do not advocate surgery. However, we advised the patient to continue isometric quadriceps exercises, modify his daily activities and life style. Our plan of surgery for chondromatosis left us with the choice to perform a high tibial osteotomy (HTO) or arthroplasty, if required in the future. The residual pain experienced by the patient is currently being controlled by analgesia.

CONCLUSION

Synovial chondromatosis is a rare benign condition but can be highly aggressive and devastating. This case, with its rare presentation of both intra and extra-articular disease, reflects the importance of thorough clinical assessment, appropriate use of investigation, and a careful pre-operative planning of synovial chondromatosis.

REFERENCES

1. Jefferys TE. Synovial Chondromatosis. *J Bone Joint Surg Br.* 1967 Aug; 49(3):530-4.
2. Miligram JW. Synovial Osteochondromatosis. *J Bone Joint Surg Am.* 1977 Sep;59(6):792-801.
3. Ackerman D, Lett P, Galat DD Jr, Parvizi J, Stuart MJ. Results of total hip and total knee arthroplasties in patients with synovial chondromatosis. *J Arthroplasty.* 2008 Apr;23(3):395-400.
4. Canale ST, Beatty JH, editors. *Campbell's Operative Orthopaedics.* 11th ed. Philadelphia: Mosby Elsevier; 2007.
5. Sim FH, Dahlin DC, Ivins JC. Extraarticular synovial chondromatosis. *J Bone Joint Surg Am.* 1977 Jun;59(4):492-5.
6. Sah AP, Geller DS, Mankin HJ, Rosenberg AE, Delaney TF, Wright CD, Hornicek FJ. Malignant transformation of synovial chondromatosis of shoulder to chondrosarcoma. *J Bone Joint Surg Am.* 2007 Jun;89(6):1321-8.
7. Bullough PG. *Orthopaedic pathology.* 4th ed. New York: Mosby; 2004.
8. Symeonides PJ. Bursal Chondromatosis. *J Bone Joint Surg Br.* 1966 May; 48(2):371-3.
9. Dunn AW, Whisler JH. Synovial chondromatosis of knee with associated extracapsular chondromas. *J Bone Joint Surg Am.* 1973 Dec;55(8):1747-8.
10. Maurice H, Crone M, Watt I. Synovial Chondromatosis. *J Bone Joint Surg Br.* 1988 Nov;70(5):807-11.



Instructions to Authors

The JSMDC agrees to accept manuscripts prepared in accordance with the 'Uniform Requirements submitted to the Biomedical Journals' as approved by the International Committee of Medical Journal Editors (ICMJE) guidelines, published in the British Medical Journal 1991 ; 302:334-41 , printed in the JCPSP, Vol. 3 No. 2, April-June, 1993, updated and reprinted in 2003 , 2007 , 2008 and September 2012, Vol. 22 (9).

Scope: JSMDC, the Journal of Sharif Medical & Dental College publishes original articles concerning research in Basics and Clinical Sciences and Allied Health Sciences.

Ethical / Legal considerations: A submitted manuscript must be an original contribution not previously published (except as an abstract or preliminary report), must not be under consideration for publication elsewhere, and if accepted, it must not be published elsewhere in similar form. Each person listed as an author is expected to have participated in the study to a significant extent. Although the editors and referees make every effort to ensure the validity of published manuscripts, the final responsibility rests with the authors, not with the Journal, its editors, or the publisher. All manuscripts must be submitted by email to the address editor@jsmdc.pk

Financial disclosure: Each author warrants that he or she has no commercial associations (e.g., consultancies, stock ownership, equity interest, patent/licensing arrangements, etc.) that might pose a conflict of interest in connection with the submitted article, except as disclosed on a separate attachment. All funding sources supporting the Work and all institutional or corporate affiliations of the authors are acknowledged in a footnote in the Work.

Patient anonymity and informed consent: It is the author's responsibility to ensure that a patient's anonymity be carefully protected and to verify that any experimental investigation with human subjects reported in the manuscript was performed with informed consent and following all the guidelines for experimental investigation with human subjects required by the institution(s) with which all the authors are affiliated.

Copyright: All authors must sign a copy of JSMDC's Authorship Responsibility, Financial Disclosure, and Copyright Transfer form and submit it with the article. "In consideration of the Journal of Sharif Medical and Dental College's taking action in reviewing and editing my (our) submission, the author(s) undersigned hereby transfer(s), assign(s), or otherwise convey(s) all copyright ownership to the Journal of Sharif Medical and Dental College in the event that such work is published by the Journal of Sharif Medical and Dental College."

Permissions: Authors must submit written permission from the copyright owner (usually the publisher) to use direct quotations, tables, or illustrations that have appeared in copyrighted form elsewhere, along with complete details about the source.

Original articles: Should normally report original research of relevance to clinical medicine. It should contain a structured abstract of about 250 words. Three to 10 keywords should be given for an original article as per MeSH (Medical Subject Headings). There should be three to five tables or illustrations. The data should be supported with 20 to 25 references. Most of the references should be from last five years from the date of submission.

Clinical case reports: Must be of academic and educational value and provide relevance of the disease being reported as unusual. Brief or negative research findings may appear in the section. It should have a non-structured abstract of about 100-150 words (case specific) with around 5-6 references and 3 keywords.

Letters to the editor: There are different types of Letters to the Editor (LTE). If the purposes of the LTE is to comment on a published article, the first sentence of the LTE should include the name of the published article's first author along with the title of the published article. The article discussed should then be referenced at this time or should be referenced at the end of the LTE. If the LTE is a reply to a previously submitted LTE, the first sentence should include the name of the letter's author and cite the letter as reference. The previously published article should then be referenced as well either in the body of the text or at the end of the response to the LTE.

Photo essays: The journal accepts manuscripts for consideration as photo essays. These essays include the visual presentation of material where the primary emphasis is on the images. These images can include color images,

Instructions to Authors

angiograms, optical coherence tomography, histologic sections, x-rays, ultrasounds, and other studies. The images can be an outstanding presentation of classic findings, atypical findings or new findings, but, the primary emphasis should be on the images. These are not case reports, but rather visual presentation of material as a teaching tool. The images need to be of the highest quality. The accompanying manuscript should be limited to a total of 300 words. A maximum of 5 separate images and 5 references can be included. All figures submitted in color are published in color, at the expense of the author. Please refer to the rest of the author instructions for other requirements for manuscripts submitted to JSMD.

Review article: Should consist of critical overview/analysis of some relatively narrow topic providing background and the recent development with the reference of original literature. It should incorporate author's original work on the same subject. The length of the review article should be of 2500 to 3000 words with minimum of 40 and maximum of 60 references. It should have non-structured abstract of 150 words with minimum 3 key words. An author can write a review article only if he/she has written a minimum of three original research articles and some case reports on the same topic.

Other sections: The journal also accepts manuscripts for other sections such as Diagnostic & Therapeutic Challenges, Clinicopathologic Correlations, Surgical Techniques, and New Instruments. All manuscripts must be double-spaced, include a Title Page and be no more than 5 pages of manuscript text in length, and should include no more than 4 figures and 5 references. The format for all submitted manuscripts is basically as described above with a few exceptions. Diagnostic & Therapeutic Challenges require no abstract and have no limit for figures and references. Surgical Techniques and Clinicopathologic Correlations are treated like a full manuscript and require an abstract. All Correspondence and New Instruments should have a standard title page with full length title, running title, and author information. Key words and summary statement should be on the second page. A formal abstract is not required by the journal for Correspondence and New Instruments. A summary statement of 50 words is necessary for publication and indexing and must be included at the time of submission. All pages must be numbered starting with the title page being page one. Each figure must be submitted separately. All color figures will be published in this section at the authors' expense. Authors who submit figures in color do so with the understanding that the figures will be published in color and at their expense.

Between 3 to 10 key words should be given for all the category of manuscripts under the abstracts as per mesh [medical subject heading]. The article must be submitted by email in the following format: Type double – spaced in MS Word using "Verdana" font size 12 leaving ONE INCH margin on ALL SIDES. Arrange contents as follows:

1. Title page should be numbered as page 1, and should have on it only i.e. the title, name(s) of the author(s), the institution(s) of author(s), address for reprints and inquiries, and the name(s) of sponsoring organization(s).
2. Structured abstract: The abstract should be divided into four sections with the following headings: Purpose, Material and Methods, Results, and Conclusion.
3. Text: The introduction should be pertinent to the study but not an in-depth review of the literature. The materials, subjects, and methods should be clearly defined. Make the results as concise as possible. The discussion is an explanation of the results of the study and should limit itself to the subject matter of the paper. Write the whole paper in "active voice", and avoid "passive voice".
4. Acknowledgements: Keep these to an absolute minimum, and be specific, e.g. "Thanks are due to Mr...for Fig. 2".
5. References: Must be numbered consecutively, according to their appearance in text according to VANCOUVER style of referencing. Once a reference is cited, all subsequent citations should be to the original number. Reference to studies that have been accepted but not yet published should indicate where they will be published. The author is responsible for complete and accurate references, including the proper capitalization and accent marks used in foreign language publications.
6. Figures: Should be numbered in order of appearance in the text. Each figure should have a figure's number, the last names of authors. Legends for the figures should be typed DOUBLE – SPACED and should include description of features shown, names of authors, names of structures, kind of stain, magnification, etc.
7. Tables: Should be typed double – spaced, with nothing underlined. Please triple – check all numbers and percentages. Previously published material and figures should include permission to reproduce from the original publication and original author. Photographs with faces should be accompanied by permission to publish from the

Instructions to Authors

subject of the photograph or by a parent in case of minor. Colored photographs should be submitted in JPEG format. Journal reserves the right to charge authors for reproduction of colored pictures. The journal only accepts manuscripts in English.

Peer review: Every paper will be read by at least two editors of the Editorial Board. The papers selected will then be sent to two external reviewers. If statistical analysis is included, further examination by a staff statistician will be carried out. The staff Bibliographer also examines and authenticates the references and checks for plagiarism.

Authorship criteria: As stated in the uniform requirements, credit for authorship requires substantial contributions to (a) the conception and design or analysis and interpretation of the data, (b) the drafting of the article or critical revision for important intellectual content, critical appraisal of findings with literature search and actual write up of manuscript, (c) final approval of the version to be published. Each author must sign a statement attesting that he or she fulfils the authorship criteria of the Uniform Requirements. Up to six authors are allowed in a single institution study. In a multi institution and international collaboration research Editorial Board shall guide on individual case basis. JSMDC strongly discourages gift authorship. More supervision, collection of data, statistical analysis and language correction do not grant authorship rights. Ideally all authors should belong to same department of an institute, except for multi-center and multi-specialty studies. The Journal discourages submission of more than one article dealing with related aspects of the same study. The Journal also discourages the submission of case reports unless unreported from Pakistan. Unusual but already reported cases should, therefore, be submitted as letters to the editor.

Plagiarism policy: JSMDC observes/follows the ICMJE, PMDC and HEC guidelines/criteria for all types of plagiarism. The same can be accessed at www.icmje.org, www.pmdc and www.hec.gov.pk. It is the authors' responsibility to apprise themselves of plagiarism in any form including paraphrasing and self-plagiarism. Manuscripts submitted to JSMDC can be sent to HEC, other medical journals' editors and international agencies for authentication of originality. The disciplinary committee of JSMDC would deal with cases of plagiarism and comprise of the staff, editors and the Chief Editor or his representative.

For a plagiarized article in processing, the identification of act will lead to dropping of article from further processing/consideration of publication. The author will be required to give an explanation on demand. In case of an unsatisfactory reply, the matter will be referred to the disciplinary committee that may decide the course of action. For a published articles, the allegedly plagiarized article will be temporarily retracted from publication and a notice to the effect will be published in the JSMDC. The author will be served an explanation demand. In case of unsatisfactory response in the stipulated time or unsatisfactory explanation, the article will be permanently retracted and the author will be on watch. HEC, PMDC and author's institute will also be informed. The author(s) will have to provide documentary proof of retraction from publication, if such a defense is pleaded. Those claiming intellectual / idea or data theft of an article must provide documentary proof in their claim. JSMDC will be using plagiarism detection software and authors are encouraged to review their manuscripts through internationally recognized plagiarism detection softwares before submission. For example authors and researchers can use TURNITIN Software to screen their work before submission by visiting <http://www.turnitin.com>.

Acceptance of articles: Please check all grammatical mistakes using MS word spell checker before submission. Incomplete manuscripts and papers with excessive number of grammatical mistakes will not be acknowledged and will be returned to the authors. All papers will be subject to peer review and if necessary, revisions will be requested. The journal will also consider for publication letters, short notes on useful diagnostic and therapeutic tips, announcements, and interesting photographic documentations.

After acceptance: Page proofs and corrections. Corresponding authors will receive electronic page proofs to check the copyedited and typeset article before publication. Portable document format (PDF) files of the typeset pages and support documents (e.g., reprint order form) will be sent to the corresponding author by e-mail. Complete instructions will be provided with the e-mail for downloading and printing the files and for emailing the corrected page proofs to the publisher. Those authors without an e-mail address will not receive page proofs. It is author's responsibility to ensure a working email ID. It is also the author's responsibility to ensure that there are no errors in the proofs. Authors must review the proofs thoroughly as errata will not be permitted except for special circumstances. Changes that have been made to conform to journal style will stand if they do not alter the authors' meaning. Only the most critical

Instructions to Authors

changes to the accuracy of the content will be made. Changes that are stylistic or are a reworking of previously accepted material will be disallowed. JSMDc reserves the right to deny any changes that do not affect the accuracy of the content. Proofs must be checked carefully and corrections emailed within 24 to 48 hours of receipt.

It is duly notified that a processing fees of Rs. 1000/- will be charged at the time of initial manuscript submission in the form of bank draft made in favour of Sharif Medical & Dental College. In case of printing color photographs, additional charges may apply as the need arises.





SHARIF TRUST



Sharif Medical & Dental College

Sharif Medical City Road, Off Raiwind Road, Jati Umra, Lahore 54000, Pakistan.

Tel: +92-4237860101-4 Fax: +92-4237860122 UAN- 042-111-123-786

E-mail: editor@jsmdc.pk Web: www.sharifmedicalcity.org